

## Case Report

# A Case Report on Vogt-Koyanagi-Harada Disease Seen at a Tertiary Hospital in the Philippines

Tathiana T. Marcelo, MD\*; Eleonore B. Iguban, MD\*

Department of Ophthalmology, Rizal Medical Center, Pasig Boulevard, Pasig City, Philippines

### \*Corresponding authors

Tathiana T. Marcelo, MD

Department of Ophthalmology, Rizal Medical Center, Pasig Boulevard, Pasig City, Philippines; E-mail: [tathianamarcelo@yahoo.com](mailto:tathianamarcelo@yahoo.com)

Eleonore B. Iguban, MD

Department of Ophthalmology, Rizal Medical Center, Pasig Boulevard, Pasig City, Philippines; E-mail: [eleonore\\_i@yahoo.com](mailto:eleonore_i@yahoo.com)

### Article information

Received: August 2<sup>nd</sup>, 2018; Revised: September 3<sup>rd</sup>, 2018; Accepted: September 5<sup>th</sup>, 2018; Published: September 24<sup>th</sup>, 2018

### Cite this article

Marcelo TT, Iguban EB. A case report on Vogt-Koyanagi-Harada disease seen at a tertiary hospital in the Philippines. *Ophthalmol Open J.* 2018; 3(1): 1-4.

doi: [10.17140/OOJ-3-116](https://doi.org/10.17140/OOJ-3-116)

### ABSTRACT

Vogt-Koyanagi-Harada disease (VKHD) is defined as a bilateral granulomatous panuveitis that affects pigmented structures, such as the eye, inner ear, meninges, skin and hair. Up until this point, the exact pathogenesis is still a matter of inquiry. The most accepted mechanism involves autoimmune reaction among tissues that contains melanocytes. This disease has been described to have four stages: prodromal, acute uveitic, convalescent and chronic/recurrent stage, all of which affecting pigmented structures in the body. Early diagnosis and meticulous use of steroids has remained as the mainstay treatment, however, poor prognosis for individuals who presented with complications in the initial consultation has been associated with a poor final visual acuity. The main objective of presenting this classic case of Vogt-Koyanagi-Harada disease is describing its chronic systemic course, and the possible medical and surgical management for the disease and its complications.

### Keywords

Vogt-Koyanagi-Harada Disease (VKHD); Vitiligo; Bilateral granulomatous panuveitis; Autoimmune disorder.

### INTRODUCTION

Vogt-Koyanagi-Harada disease (VKHD), initially described as an uveomeningoencephalitic syndrome, is a constellation of clinical symptoms and signs that involves the eye, inner ear, meninges, skin and hair. It is a systemic granulomatous autoimmune disease that targets melanocyte-rich tissues.

It was in the 19<sup>th</sup> century when Vogt, Harada and Koyanagi first described the disease. VKH disease occurs more frequently among individuals of pigmented skin, such as Asians, Middle Easterners, Hispanics and Native Americans. However, it is interesting to note that it is infrequent among persons of African descent.<sup>1</sup> Different studies point out to the sex predilection of this

disease, some stating that it has a sexual predilection and the others stating that it does not. In the Philippines, in an article published by the Philippine Journal of Ophthalmology by Castillo et al, they were able to note that among patients diagnosed to have VKH disease in the Uveitis Clinic of the Philippine General Hospital from 1985 to 1987, the sex ratio was 2:3 (M:F).<sup>2</sup> Women account for 55 to 78% of VKHD patients in the United States and approximately 38% in Japan, showing a global variation in gender predilection.<sup>3</sup>

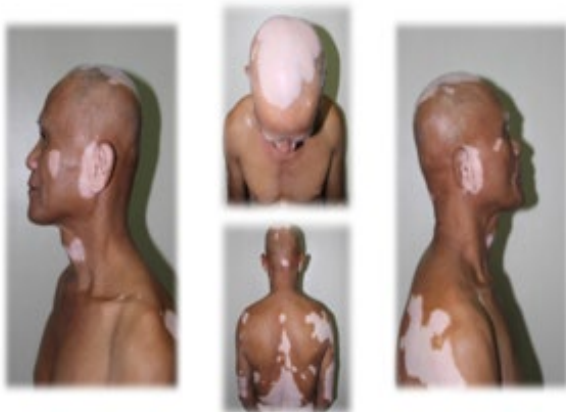Theories revolve around the possibility that a T-cell mediated autoimmune reaction against one or more antigens associated with melanocytes, melanin, and retinal pigment epithelium (RPE) may play a major role in the disease.

## CASE REPORT

We are presented with a case of a 59-years-old-male who came in with a chief complaint of blurring of vision described to be gradual and progressive, more noted on the right eye than on the left eye, 3-years prior to consult.

The history of present illness started 14-years prior to consult when the patient noted patches of lighter skin that appeared on the patient's lower extremities and small round and oval spot baldness. He denies any history of joint pain, vascular diseases, and recurrent wounds in all parts of neither the body nor taking any of maintenance medication. There was no noted ringing in the ears, decrease in hearing and episodes of persistent headache. Patient does not recall having blurring of vision at this point. He also denies any history of eye trauma (Figure 1).

**Figure 1.** Generalized Vitiligo (pictures were taken with patient's permission through a written consent)



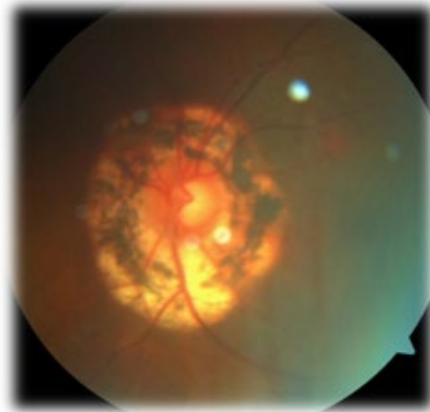
Seven-years prior to consult, still with the aforementioned signs and symptoms, the spot baldness and patches of lighter skin increased in size and number, now involving the upper extremities. Patches of white lashes were also present. There was a noted loss of axillary and pubic hair. Photophobia was also noted. There was no change in the patient's hearing and refutes any incident of persistent headache. Still, no consult was done and no medications were taken.

Three-years prior to consult, patient noticed hearing loss and ringing in the ears. He also experienced gradual and progressive blurring of vision on both eyes, both at near and distance described to be cloudy in character and still associated with photophobia. There was no eye pain noted. Patient denies any neck stiffness or recurrent headache. Persistence of these symptoms prompted the patient to seek consult at our institution.

On initial ocular examination, the visual acuity on the right eye was hand movement with good light projection, and 6/60 best corrected to 6/30 on the left eye. Poliosis was present in both

eyes. The cornea has multiple keratic precipitates and multiple stromal opacities bilaterally however; there was no noted anterior chamber reaction. Perilimbal vitiligo was also noted. Both eyes had significant cataractous lenses. The intraocular pressure for both eyes was normal (Figure 2).

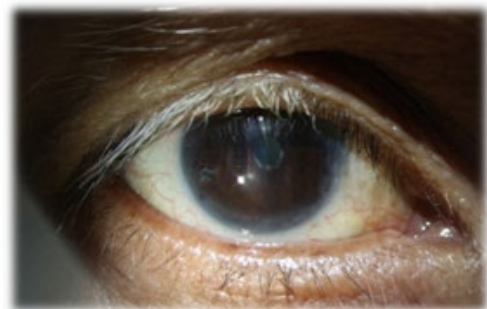**Figure 2.** Fundus Photo of the Left Eye Revealing a Hazy Media and the Classic Sunset Glow Fundus (pictures were taken with patient's permission through a written consent)



On indirect ophthalmoscopy, sunset glow fundus was noted on the left eye with multiple hyperpigmented nummular lesions with hypopigmented border at the mid periphery, seen mostly at the superior nasal and temporal quadrants. There was no view on the right eye and B-scan was done which revealed a thickened choroid, however the retina was attached.

The patient was initially diagnosed with VKH syndrome, cataract senile mature oculus dexter (OD), cataract senile immature oculus sinister (OS) (Figure 3).

**Figure 3.** Poliosis on both Upper and Lower Lashes (pictures were taken with patient's permission through a written consent)



The patient had serial follow-ups from the initial consult. He was started on atropine sulfate and prednisolone acetate eye drops which was gradually tapered throughout the treatment. Intraocular pressure for both eyes were normal, however, it was oc-

cludable in one quadrant and the service entertained the possibility of occlusio pupillae, therefore, a laser iridotomy on both eyes had to be done as he was also diagnosed with primary angle closure suspect, oculus uterque (OU). He was referred to ears, nose, and throat (ENT) service wherein puro tone audiometry was done which revealed sensorineural hearing loss on the left ear. He was then prescribed with Mecobalamin 500 mg/tab, 1 tablet twice daily and was advised to do a repeat pure tone audiometry after 1-year. Complete blood count, urinalysis, erythrocyte sedimentation rate and C-reactive protein were all within normal limits. To rule out any pulmonary pathology, chest X-ray was done, however it revealed normal results. Rapid plasma reagin was also nonreactive. Electroretinography and fluorescein angiography were requested, however, due to the unavailability of these tests in our institution and the financial inability of the patient to have these examination done, the aforementioned tests were not made.

After the topical medications were discontinued, the patient was observed for four months without anterior chamber (AC) reaction noted. The patient then underwent an uneventful cataract surgery *via* phacoemulsification on the right eye with a final best-corrected visual acuity (BCVA) of 6/48. Optical coherence tomography (OCT) was requested after the cataract extraction; however, the patient was already lost to follow-up.

## CASE DISCUSSION

It is believed that an autoimmune aggression is the nature of VKHD. Sugita et al described those T-cells from peripheral blood and intraocular fluid from patients with VKHD cross-reacted with tyrosinase protein and with highly homologous cytomegalovirus specific sequences. Studies conducted by Matsuda and Hammer were able to find evidences linking the interaction among lymphocytes, peripheral blood mononuclear cells and melanocytes on this disease process.<sup>4,5</sup> In separate studies, Damico and Imai sited the role of helper T-cells, Th1 cytokines, interferon gamma and interleukin-2 in the acute phase of VKHD.<sup>6,7</sup> As these new studies have surfaced, still, the primary pathological feature of this disease would be a diffuse thickening of the uveal tissues that is more noted in the choroid.

Histologic findings vary at the different stages of VKHD. Lymphocytic dominance with epithelioid cells and multinucleated giant cells is noted in the acute uveitic stage.<sup>8</sup> The phenomena of Dalen-Fuchs nodules may be explained by the focal collections of retinal pigment epithelium (RPE), macrophages, epithelioid cells and lymphocytes found along the RPE and Bruch's membrane.<sup>8</sup>

Nongranulomatous inflammation is said to be found during the convalescent stage. The classic sunset glow fundus was described by Rao to be a choroidal melanocyte aggression wherein there is a loss of melanin granules that results in a pale and depigmented choroid. Nummular, small hypopigmented lesions especially noted in the periphery of the fundus was further believed to be produced by focal chorioretinal adhesions and subsequent atrophy.<sup>8</sup>

Granulomatous damage to the choriocapillaries is observed during the chronic recurrent stage. Subretinal neovascularization, fibrosis and involvement of the choriocapillaries can be seen in this stage.<sup>8</sup>

Nevertheless, the diagnosis if VKHD is still primarily clinical. As in this case, the attending service had to rely heavily on clinical examination due to unavailability of the tests that can contribute to the diagnosis of the disease. Ancillary examinations such as OCT, fluorescein angiography, ocular ultrasonography and indocyanine green angiography can help one with the diagnosis of VKHD cases.

The mainstay of treatment of VKHD is the meticulous use of steroids to control the damage induced by the autoimmune reaction. It is believed that aggressive treatment with steroids can result to less structural damage to the melanocyte containing tissues, thus somehow preventing complications and recurrence.<sup>9</sup> As in this case, we caught the disease 14-years later since the commencement of its course, where there were already multiple keratic precipitates with a quiet anterior chamber, except that the complications such as cataract and the possibility of glaucoma is already present. Use of immunomodulatory has also been considered in the treatment of VKHD.

The visual prognosis of this disease lies in the early diagnosis and consequent use of corticosteroids and immunomodulators. Complications such as cataract, glaucoma and choroidal neovascularization (CNV) are not unusual in this syndrome. These complications, together with its recurrence and chronicity, are believed to instigate the sight-threatening illness that Vogt-Koyanagi-Harada disease can bring about.

## CONFLICTS OF INTEREST

The authors declare that they have no conflicts of interest.

## CONSENT

The authors have received written informed consent from the patient.

## REFERENCES

1. Rao NA, Gupta A, Dustin L, et al. Frequency of distinguishing clinical features in Vogt-Koyanagi-Harada disease. *Ophthalmology*. 2010; 117(3): 591-599. doi: [10.1016/j.ophtha.2009.08.030](https://doi.org/10.1016/j.ophtha.2009.08.030)
2. Castillo TR, Noche RR, Fajardo RV. Vogt – Koyanagi – Harada disease in the Philippines. *Philippine Journal of Ophthalmology*. 1998; 23(4): 159-162.
3. Herbort CP, Mochizuki M. Vogt-Koyanagi-Harada disease: Inquiry into the genesis of a disease name in the historical context of Switzerland and Japan. *Int Ophthalmol*. 2007; 27(2-3): 67-79. doi: [10.1007/s10792-007-9083-4](https://doi.org/10.1007/s10792-007-9083-4)

4. Matsuda H. Electron microscopic studies on Vogt-Koyanagi-Harada syndrome and sympathetic ophthalmia with special reference to the melanocyte. *Nippon Ganka Gakkai Zasshi*. 1970; 74(9): 1107-1112.
5. Hammer H. Cellular hypersensitivity to uveal pigment confirmed by leucocyte migration tests in sympathetic ophthalmitis and the Vogt-Koyanagi-Harada syndrome. *Br J Ophthalmol*. 1974 ; 58(9): 773-776.
6. Damico FM, Bezerra FT, Silva GC, Gasparin F, Yamamoto JH. New insights into Vogt-Koyanagi-Harada disease. *Arq Bras Oftalmol*. 2009; 72(3): 413-420.
7. Imai Y, Sugita M, Nakamura S, Toriyama S, Ohno S. Cytokine production and helper T cell subsets in Vogt-Koyanagi-Harada's disease. *Curr Eye Res*. 2001; 22(4): 312-318.
8. Rao NA. Pathology of Vogt-Koyanagi-Harada disease. *Int Ophthalmol*. 2007; 27(2-3): 81-85. doi: 10.1007/s10792-006-9029-2
9. Jabs DA, Rosenbaum JT, Foster CS, et al. Guidelines for the use of immunosuppressive drugs in patients with ocular inflammatory disorders: Recommendations of an expert panel. *Am J Ophthalmol*. 2000; 130(4): 492-513.