

## Case Report

# A Case of Pleomorphic Adenoma Metastasising to Contralateral Supraclavicular Lymph Node

Esmail Abdulahi Ahmed, MD<sup>1\*</sup>; Kamil Akdag, MD<sup>1</sup>; Onur Üstün, MD<sup>1</sup>; Ayça Başkadem Yılmaz, MD<sup>1</sup>; Pınar Özay Nayır, MD<sup>2</sup>; Zeynep Aydodu, MD<sup>1</sup>; Yavuz Uyar, MD<sup>1</sup>

<sup>1</sup>Department of Otorhinolaryngology-Head and Neck Surgery, Okmeydani Training and Research Hospital, Istanbul, Turkey

<sup>2</sup>Department of Pathology, Okmeydani Training and Research Hospital, Istanbul, Turkey

### \*Corresponding author

**Esmail Abdulahi Ahmed, MD**

Department of Otorhinolaryngology-Head and Neck Surgery, Okmeydani Training and Research Hospital, Darulaceze Cad. No:25 Okmeydani-Sisli, Istanbul, Turkey; Tel. 0090 507 711 32 91; E-mail: [ismodho@gmail.com](mailto:ismodho@gmail.com)

### Article information

**Received:** February 18<sup>th</sup>, 2019; **Revised:** July 23<sup>rd</sup>, 2019; **Accepted:** July 24<sup>th</sup>, 2019; **Published:** August 3<sup>rd</sup>, 2019

### Cite this article

Ahmed EA, Akdag K, Üstün O, et al. A case of pleomorphic adenoma metastasising to contralateral supraclavicular lymph node. *Otolaryngol Open J.* 2019; 5(2): 34-38. doi: [10.17140/OTLOJ-5-158](https://doi.org/10.17140/OTLOJ-5-158)

## ABSTRACT

### Introduction

Pleomorphic adenomas are the most common benign parotid tumours in all populations. Management always consists of a curative superficial parotidectomy. However, rare cases described, in which these histological benign tumors metastasize to distant sites. We present an example of a recurrent parotid pleomorphic adenoma with a contralateral supraclavicular lymph node metastasis after several surgical interventions.

### Case report

In this case, we reported a case of 29-years male with extensive metastasis in submandibular, submental and also very rarely seen contralateral supraclavicular lymph node metastasis. Parotidectomy with preservation of facial nerve and radiotherapy was given to the patient since the lesions were very aggressive.

### Conclusion

The patient had several surgical interventions, so it is essential to do meticulous resection in the first surgery to prevent local recurrence and distant metastasis.

### Keywords

Pleomorphic adenoma; Metastasizing pleomorphic adenoma; Salivary gland benign neoplasia.

## INTRODUCTION

Pleomorphic adenoma is a benign tumour that has elements of both epithelial and mesenchymal tissues. Pleomorphic adenoma is a tumour of variable capsulation characterized microscopically by architectural rather than cellular pleomorphism, most commonly with a tissue of mucoid, myxoid or chondroid appearance which consists of the salivary glands.

It consists of approximately 3% of all head and neck tumours and about 70-80% of these neoplasms occur in the major salivary glands.<sup>1</sup> The tumour most commonly found in the parotid or submandibular glands. Incidence of pleomorphic adenoma varies from 2 to 3.5% with a female preponderance, 3<sup>rd</sup> and 6<sup>th</sup>

decades are peak ages for pleomorphic adenoma. Neck irradiation is a very strong predisposing factor while the link between the development of pleomorphic adenoma and a simian virus is not clear yet.<sup>2</sup>

Although pleomorphic adenoma is a benign tumour sometimes it shows recurrence and also transformation to malignant tumour with an incidence of 2 to 7%.<sup>2</sup> This makes pleomorphic adenomas challenging to manage compared to other salivary gland tumours. On the other hand, pleomorphic adenoma shows malignant behavior with benign histology. This is a very rare entity and its incidence is not clear. There are no studies done on this form of pleomorphic except case reports.<sup>3</sup>

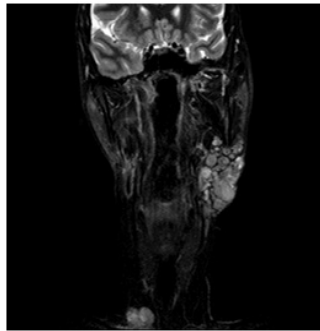
In this article, we present a very unique case of metastasizing pleomorphic adenoma having contralateral supraclavicular non symptomatic metastatic lesions. This will be first case in the literature with contralateral supraclavicular metastasis.

## CASE REPORT

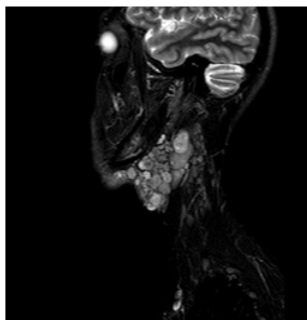
A 29-years-old male patient with complaints of a mass in left submandibular gland was referred to our hospital. The patient was not having any other significant complaints.

Clinical examination exhibited a relatively mobile, soft mass located in the left submandibular and submental neck region. Magnetic resonance imaging (MRI) revealed extensive left submandibular and submental subcutaneous mobile conglomerate lesions but what was unique for this case was a single lesion on the right supraclavicular region similar to the main lesion found incidentally on MRI (Figures 1A and 1B).

**Figure 1A.** Coronal Section of MRI also Showing Single Contralateral Supraclavicular Metastasis



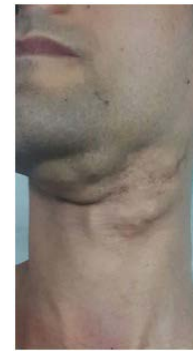**Figure 1B.** Sagittal Section of MRI Showing Extensive Submental and Submandibular Metastasis



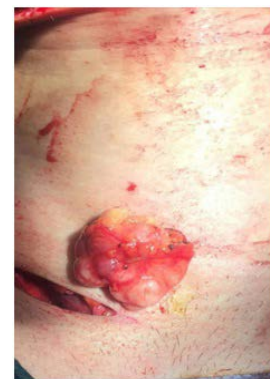The patient was operated in another hospital in 2003 and his first pathologic report after the surgery showed pleomorphic adenoma, unfortunately, surgical margins were very near to a tumour. After an extended period of irregular follow-up in 2013, the patient came up with painless swelling on the left neck just next to the scar of the previous incision. Fine needle aspiration resulted showed a pleomorphic adenoma and local excision was performed.

The patient discontinued the follow-up until 2017. He applied to our clinic with extensive submental and submandibular round and soft subcutaneous masses (Figures 2A and 2B). All other otorhinolaryngology examination and systematic examination was regular.

**Figure 2A.** Submandibular and Submental Subcutaneous Nodules and Previous Incision Scar



**Figure 2B.** Single Supraclavicular Lesion



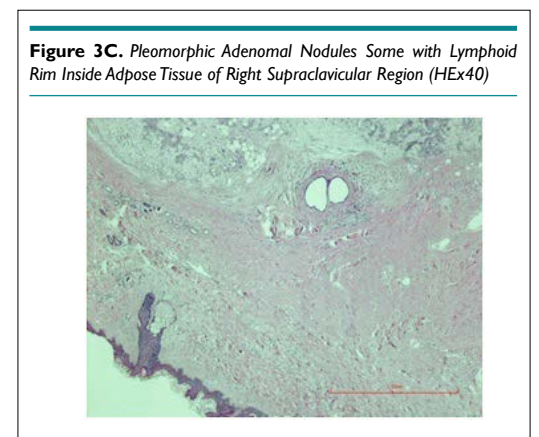
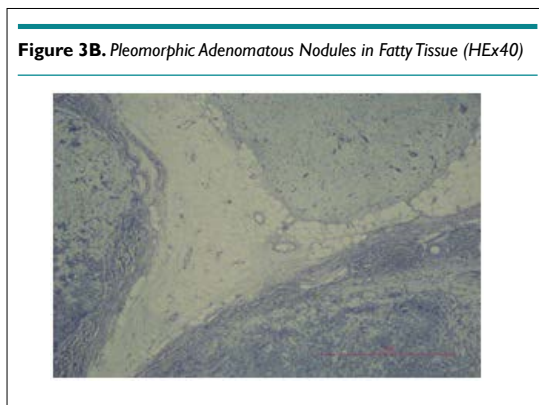
Originally tumour was in the submandibular gland but in the last recurrence, the tumour was extending to the inferior part of the parotid gland. The patient underwent total parotidectomy with facial nerve preservation and ipsilateral neck dissection.

Pathologic examination revealed a tumorous lesion in a transparent, nodular structure with a white color in different sizes, holding the entire cross-sectional surface in sections of the left parotid and neck dissection with a size of 15.5×5.5×3.5 cm with an ellipsoid skin of 7.5×1.3 cm in size, macroscopically.

On the other hand, there were some white-colored pieces in the right supraclavicular region with 3×3×1 cm size, transparent material with nodular structure and some fat tissue.

Microscopic examination of the left parotid and neck dissection showed that the chondromyxoid stroma composed of fibroblasts and epithelioid types of cells in some areas of the abortive ducts. Also in some areas, there were a more solid cellular atyp-

ia and no mitotic tumour proliferation. In the histopathological examination of the material from the right supraclavicular region, there was nodular tumour proliferation with similar microscopic features observed in the fatty tissue of the expansive parent material (Figures 3A, 3B and 3C).



In the immunohistochemical study performed, GFAP focal positivity, BCL2 focal positivity and S100 positivity were found. Ki 67 proliferation index was 1%. Histopathologically, there was no evidence of malignancy in both materials, and the findings were consistent with benign pleomorphic adenoma.

## DISCUSSION

Pleomorphic adenoma is a benign tumour that has elements of both epithelial and mesenchymal tissues. Pleomorphic adenomas

tend to transform to malignancy. Also in very rare cases, pleomorphic adenomas show clinically malignant behaviour while histologically remaining benign. This kind of tumours is called metastasizing pleomorphic adenomas (MPA).<sup>1,4</sup>

World Health Organization (WHO) classifies neoplasms that show malignant transformation as malignant epithelial tumours.<sup>1</sup> However, controversy still exists on rare occasions in which metastasis occurs without malignant transformation. Previously it was considered as benign neoplasia; however, the WHO new classification on head and neck tumours found as a malignant.<sup>1</sup> The high mortality rate of around 50% makes them considered as malignant tumours.

The exact incidence of metastasizing pleomorphic adenomas is not known. However, many cases of metastasizing pleomorphic adenoma have been reported since the early 1940s. McGarry et al<sup>5</sup> analysed 52 cases, while Knight et al<sup>6</sup> performed a systemic review of case reports from 1942 to 2014 and found 80 cases. LiVolsi and Perzin reviewed 47 cases of metastasizing pleomorphic adenoma.<sup>7</sup> Sites of metastasis were bone 36.6%, lung 33.8 and cervical lymph nodes 20.1%.<sup>6</sup>

There are several hypotheses about the mechanism of metastasis of pleomorphic adenomas: which are incomplete enucleation, direct seeding, hematogenous and lymphatic routes. Nourai et al<sup>8</sup> reported a series of 42 cases with (MPA), that incomplete excision of the primary pleomorphic adenoma was the most influential factor associated with local recurrence and distant metastasis. In this case, two previous surgical interventions were performed, and the surgical margins of the first surgery were very close to the tumour. Having previous operations supports the hypothesis that inadequate surgical excision is the primary cause of recurrence in this case. But single contra-lateral supraclavicular metastasis shows that incomplete surgery is not the only reason for metastasis.

Chen et al<sup>9</sup> reported 20 of 24 tumours metastases hematogenously, whereas 4 of 24 spread *via* the lymphatic route, while Wenig et al<sup>10</sup> also reported that 8 of 11 tumours metastasizing hematogenously and the remaining three spreading *via* lymphatic channels to nearby cervical and submandibular lymph nodes. Knight et al<sup>6</sup> found in their review of 80 cases of metastatic pleomorphic adenoma that 20% of the cases had lymphatic metastasis.

In this case, local metastasis was very extensive, extending to the inferior pole of the left parotid gland. On the other hand, contralateral neck (supraclavicular) lymph node metastasis, which is very far from the original is good evidence for the hypothesis of hematogenous and lymphatic routes of metastasis.

This case is the second case with metastasis to the contra-lateral neck. Miladi et al reported a case of a left submandibular gland pleomorphic adenoma with multiple asymptomatic lymph nodes on both sides of the neck.<sup>11</sup> All reported cases had ipsilateral lymph node metastasis, metastases to the contra-lateral supraclavicular region and latency period between recurrence and metastasis gives strong evidence to consider metastasizing pleomorphic ade-

noma as a low-grade malign tumour. Although multiple metastases considered as a poor prognostic factor,<sup>6,12</sup> the relationship between the type of metastasis and aggressivity of the tumours is not clear, and there is no study done on this.

Histological the primary tumour and recurrent pleomorphic adenoma and metastasizing pleomorphic adenoma have no significant difference between them. All are composed of a mixture of benign-appearing epithelial and mesenchymal components of a pleomorphic adenoma. However, histology is not a predictive factor for its ability to metastasis. Also, currently, there is no way to predict which tumour have a risk of metastasis. Only Knight et al found that younger age presentation of pleomorphic adenoma could be a risk factor for developing of metastasizing pleomorphic adenoma.<sup>6</sup>

The exact mechanism of the metastatic behaviour of pleomorphic adenoma is still unknown. Hypercellularity, hyalinization, cellular neoplasia and mitosis are characteristic features of the malignant transformation of pleomorphic adenoma to carcinoma ex-pleomorphic adenoma, but these features are not encountered in metastasizing pleomorphic adenoma.<sup>13</sup>

Hoorweg et al<sup>14</sup> stated that the expression of apoptosis-related proteins and markers of cell proliferation activity like (p 53, Bcl-2, MIB1, CD 105, p27, p21) no significant difference was found between metastasizing pleomorphic adenoma and benign pleomorphic adenoma.

Flow cytometric analysis still is not predictive for which kind of pleomorphic adenoma having the risk of metastasis. Mariano et al found that rearrangements of 3 p and 9 p have a relationship with metastatic pleomorphic adenoma and reported that deletions of 3 p are frequently found in a large variety of malignant epithelial neoplasm.<sup>15</sup> Deletion of one or more tumour suppressor genes may be significant in the metastatic progression period of some pleomorphic adenomas.<sup>16</sup> Some authors reported that metastasizing pleomorphic adenoma is an intermediate link benign pleomorphic adenoma and malign pleomorphic adenoma.

Weissferdt et al<sup>17</sup> published a case of a carcinoma ex pleomorphic adenoma with lung metastases composed exclusively of benign elements, showing histological evidence for the link between metastatic pleomorphic adenoma and carcinoma ex-pleomorphic adenoma. Although there is no clear genetic evidence for metastasizing pleomorphic adenoma, the accumulation of key genetic alterations is the most rational explanation up to now.

Recently some authors suggested investigation with positron emission tomography (PET) for local recurrence to detect metastasis because most of the reported cases have more than one recurrence before metastasis detected.<sup>6</sup> In this case, we scanned with positron emission tomography-computed tomography (PET-CT) for metastasis, and there were no other sites of metastasis.

The most preferred treatment option is surgery, and total parotidectomy is performed with conserving the facial nerve to

achieve control and tumour-free survival. Nourai et al supported parotidectomy with preservation of facial nerve rather than inoculation.<sup>8</sup> Witt et al reported in their study by comparing total parotidectomy, superficial parotidectomy, and extracapsular dissection techniques, that only capsular rupture is a very important factor which resulted in a significantly higher rate of recurrence and did not vary among surgical approaches.<sup>2</sup>

Radiotherapy not routinely indicated for all patients; still, there is no clear evidence for the role of radiation and chemotherapy in the treatment and prevention of metastasis. But in Liu et al<sup>18</sup> reported in a retrospective study of 128 patients, 55 patients received radiotherapy, and the primary reason for radiation was recurrence after surgery. They also presented that they achieved local control in 13 of 16 patients (82%) at ten years with a median dose of 45 Gy. While local control with surgery alone achieved in 1 out of 17 patients. Chen et al<sup>19</sup> and Wallace et al<sup>20</sup> reported local control of 94% and 75% respectively, with combined surgery and radiotherapy. In this case with a multi-disciplined approach, the patient had radiotherapy and no recurrence seen until in our regular follow-ups.

## CONCLUSION

As reported in the literature, the first surgery is critical, especially in young female patients. its strongly recommended to do apparent surgery and avoid capsular rupture. So it's also essential to investigate for metastasis and treat them as a low-grade malignant tumour.

## CONSENT

The authors have received written informed consent from the patient.

## CONFLICTS OF INTEREST

The authors declare that they have no conflicts of interest.

## REFERENCES

1. Barnes DSL, Eveson JW, Reichart P. World Health Organization (WHO) classification of Tumours. *Pathol Genet Head Neck Tumours*. 2005; 209-281. Web site. <https://whobluebooks.iarc.fr/>. Accessed February 16, 2019.
2. Witt RL, Eisele DW, Morton RP, Nicolai P, Poorten VV, Zbären P. Etiology and management of recurrent parotid pleomorphic adenoma. *Laryngoscope*. 2015; 125(4): 888-893. doi: 10.1002/lary.24964
3. Malard O, Wagner R, Joubert M, et al. Prognostic factors for secondary recurrence of pleomorphic adenoma: A 20-year, retrospective study. *J Laryngol Otol*. 2013; 127(9): 902-907. doi: 10.1017/S0022215113001801
4. Young VS, Viktil E, Loberg EM, Enden T. Benign metastasizing pleomorphic adenoma in liver mimicking synchronic meta-



- static disease from colorectal cancer: A case report with emphasis on imaging findings. *Acta Radiol Open*. 2015; 4(8): 1-5. doi: 10.1177/2058460115594199
5. McGarry JG, Redmond M, Tuffy JB, Wilson L, Looby S. Metastatic pleomorphic adenoma to the supraspinatus muscle: A case report and review of a rare aggressive clinical entity. *J Radiol Case Rep*. 2015; 9(10): 1-8. doi: 10.3941/jrcr.v9i10.2283
6. Knight J, Ratnasingham K. Metastasising pleomorphic adenoma: Systematic review. *Int. J. Surg*. 2015; 19: 137-145. doi: 10.1016/j.ijso.2015.04.084
7. LiVolsi VA, Perzin KH. Malignant mixed tumors arising in salivary glands. I. Carcinomas arising in benign mixed tumors: A clinicopathologic study. *Cancer*. 1977; 39(5): 2209-2230. doi: 10.1002/1097-0142(197705)39:5<2209::aid-cnrcr2820390540>3.0.co;2-8
8. Nouraei SA, Ferguson MS, Clarke PM, et al., Metastasizing pleomorphic salivary adenoma. *Arch Otolaryngol Head Neck Surg*. 2006; 132(7): 788-793. doi: 10.1001/archotol.132.7.788
9. Myers EN, Chen Ih, Tu Hy. Pleomorphic adenoma of the parotid gland metastasizing to the cervical lymph node. *Otolaryngol Head Neck Surg*. 2000; 122(3): 455-457. doi: 10.1067/mhn.2000.98360
10. Wenig BM, Hitchcock CL, Ellis GL, Gnepp DR. Metastasizing mixed tumor of salivary glands. A clinicopathologic and flow cytometric analysis. *Am J Surg Pathol*. 1992; 16(9): 845-858.
11. Marchetti A, Padova RA, Vercelli AG, et al. *Pathologica*. 2010; 102(3): 119-126.
12. Steele NP, Wenig BM, Sessions RB. A case of pleomorphic adenoma of the parotid gland metastasizing to a mediastinal lymph node. *Am J Otolaryngol*. 2007; 28(2): 130-133. doi: 10.1016/j.amjoto.2006.07.002
13. El-Naggar A, Batsakis JG, Kessler S. Benign metastatic mixed tumours or unrecognized salivary carcinomas? *J Laryngol Otol*. 1988; 102(9): 810-812. doi: 10.1017/S0022215100106528
14. Hoorweg JJ, Hilgers FJ, Keus RB, Zoetmulder FA, Loftus BM. Metastasizing pleomorphic adenoma: a report of three cases. *Eur J Surg Oncol*. 1998; 24(5): 452-455. doi: 10.1016/S0748-7983(98)92651-8
15. Mariano FV, Gondak Rde O, Martins AS, et al., Genomic copy number alterations of primary and secondary metastasizing pleomorphic adenomas. *Histopathology*. 2015; 67(3): 410-415. doi: 10.1111/his.12655
16. Bradley PJ. Metastasizing pleomorphic salivary adenoma' should now be considered a low-grade malignancy with a lethal potential. *Curr Opin Otolaryngol Head Neck Surg*. 2005; 13(2): 123-126. doi: 10.1097/01.moo.0000153450.87288.2a
17. Weissferdt A, Langman G. An intracapsular carcinoma ex pleomorphic adenoma with lung metastases composed exclusively of benign elements: Histological evidence of a continuum between metastasizing pleomorphic adenoma and carcinoma ex pleomorphic adenoma. *Pathol Res Pract*. 2010; 206(7): 480-483. doi: 10.1016/j.prp.2009.07.008
18. Liu FF, Rotstein L, Davison AJ, et al. Benign parotid adenomas: A review of the princess margaret hospital experience. *Head Neck*. 1995; 17(3): 177-183. doi: 10.1002/hed.2880170302
19. Chen AM, Garcia J, Bucci MK, Quivey JM, Eisele DW. Recurrent pleomorphic adenoma of the parotid gland: Long-term outcome of patients treated with radiation therapy. *Int J Radiat Oncol Biol Phys*. 2006; 66(4): 1031-1035. doi: 10.1016/j.ijrobp.2006.06.036
20. Wallace AS, Morris CG, Kirwan JM, Werning JW, Mendenhall WM. Radiotherapy for pleomorphic adenoma. *Am J Otolaryngol*. 2013; 34(1): 36-40. doi: 10.1016/j.amjoto.2012.08.002