

## Case Report

# A Clonorchis Sinensis in the Gallbladder: A Rare Case in Kuwait

Ahmad E. Al-Mulla, MD\*; Fawazia Ashkanani, MD, FRCSI; Ali Al-Tabeeh, MD; Raghad Al-Huzaim, MD; Lulwah Al-Saidan, MD

Department of Surgery, Farwaniya Hospital, Ministry of Health Kuwait, Sabah Al-Nasser, Block 6, P. O. Box 13373, Farwaniya 81004, Farwaniya, Kuwait

### \*Corresponding author

Ahmad E. Al-Mulla, MD

Senior Specialist General Surgery and Bariatric Surgery, Kuwait Board of General Surgery, Fellowship Minimal Invasive and Bariatric and Endoscopy, Department of Surgery, Farwaniya Hospital, Ministry of Health Kuwait, Sabah Al-Nasser, Block 6, P. O. Box 13373, Farwaniya 81004, Farwaniya, Kuwait; Tel. 0096524888000, 00965-99833454; E-mail: [draalmulla2007@gmail.com](mailto:draalmulla2007@gmail.com)

### Article information

Received: May 10<sup>th</sup>, 2021; Revised: May 28<sup>th</sup>, 2021; Accepted: May 28<sup>th</sup>, 2021; Published: May 31<sup>st</sup>, 2021

### Cite this article

Al-Mulla AE, Ashkanani F, Al-Tabeeh A, Al-Huzaim R, Al-Saidan L. A clonorchis sinensis in the gallbladder: A rare case in Kuwait. *Surg Res Open J.* 2021; 6(1): 5-7. doi: [10.17140/SROJ-6-125](https://doi.org/10.17140/SROJ-6-125)

## ABSTRACT

*Clonorchis Sinensis* is an important foodborne pathogen. It is actively transmitted in far-East countries and Asia, especially in China. It enters the biliary system *via* ingestion of infected cysts. It is exceedingly rare to encounter such a presentation in the Middle East, particular in Kuwait. The presence of liver fluke in the biliary system may lead to adverse complications. We are presenting a case report describing quite an unusual gallbladder finding in a 55-year-old Chinese lady.

### Keywords

*Clonorchis sinensis*; Gallbladder; Acute cholecystitis; Liver fluke.

## INTRODUCTION

*Clonorchis Sinensis* (Chinese or oriental liver fluke) is an important foodborne pathogen and a cause of liver disease. It was first described in 1874 by a British physician, James McConnell, at the medical college hospital in Calcutta, India.

It is considered an active infection in countries such as Korea, Russia, Vietnam, and China. Most infections (about 85%) occur in China.<sup>1</sup>

The parasite passes in three lifecycles in different hosts: initially, the freshwater snail, the intermediate host, freshwater fish, the second intermediate host, and finally, in mammals or humans as a definitive host.

An estimate of 19 million people is infected, and 1.5-2 million show symptoms and complications. However, these incidences have been declining.<sup>2,3</sup>

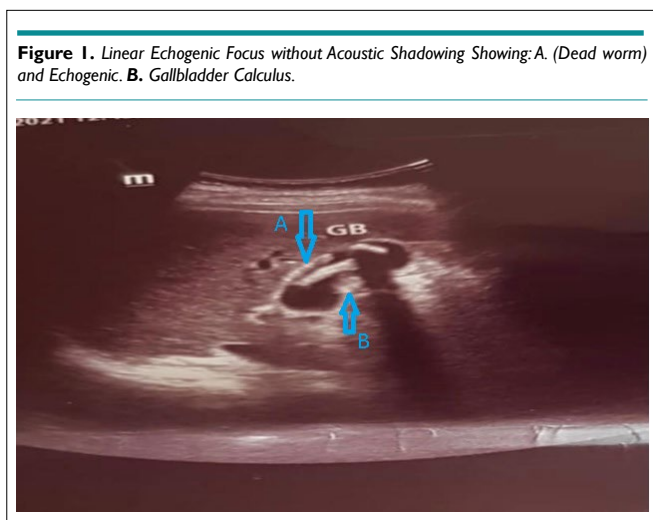
We present a 55-year-old Chinese lady with four days history of acute right upper quadrant pain caused by the gallbladder infected with the *C. Sinensis* parasite. It is exceedingly rare in Kuwait.

## CASE PRESENTATION

A 55-year-old lady, admitted through our surgical outpatient department, complaining of 3-years history of the right upper quadrant pain that increased significantly in the last four-days.

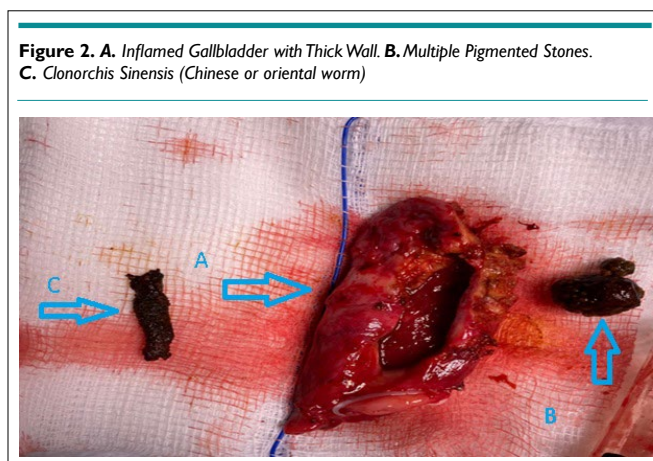
The patient has no background history of any medical illness. However, she had a previous caesarean section. She described the pain as colicky, starting at the right upper and epigastric region, and radiating to the right shoulder. This pain is aggravated by fatty meals and relieved either with painkillers or spontaneously upon resting.

Upon examination, she was vitally stable: Pulse 88 bpm, BP 120/88 mmHg, and temperature 37.5 °C. Abdominal examination: mild upper abdominal pain with negative murphy's sign. Laboratory blood test was routine, including renal and liver profile. We ordered Ultrasound, and the result was: one linear echogenic focus without acoustic shadowing (dead worm) and echogenic gallbladder calculus (Figure 1). The patient was booked for laparoscopic cholecystectomy.



### Intra-Operative Finding

Acutely inflamed gallbladder with thick wall and a complex anatomy. Cholecystectomy was done laparoscopically, with a drain fixed. The gallbladder was removed and opened, which showed stones and a dead worm (Figure2).



### Post-Operative Course

The patient stayed in the ward for four days on broad-spectrum antibiotics (Tazocin 4.5 gm, metronidazole 500 mg intravenous); we removed the drain after reaching a minimal amount. The parasitology report: liver fluke supp. *C. Sinensis* (Albendazole 10 mg/kg/day for 7-days) was started before discharge, after discussing the case with a microbiologist. The first surgical outpatient department (OPD) visit was uneventful. She was doing well, tolerating diet and no abdominal pain, and the wounds were clean. Her histopathology report indicated acute cholecystitis. Stone's analysis showed the presence of *C. Sinensis* eggs.

### DISCUSSION

*Clonorchis Sinensis* species pass through different intermittent hosts until finally settling in mammals and humans. A suitable water snail

initially ingests them, later released into the water as cercariae.

The second host is the freshwater fish which allow them to develop into metacercaria. It is finally consumed by mammals or humans, who settle as the definitive host. The metacercaria exocyst in the duodenum ascends to the biliary system, but rarely into the gallbladder and pancreatic duct, via the ampulla of water.<sup>2</sup>

The *C. Sinensis* feed on the bile and biliary system epithelium, causing chronic inflammation, which leads to many conditions. These conditions range from mild to a rather maleficent presentation, namely Cholelithiasis, Pyogenic Cholangitis, Obstructive Jaundice, Acute Cholecystitis, Pancreatitis, and Cholangiocarcinoma.<sup>4,7</sup>

Several studies were describing the relationship between parasite infection to stone formation. Qiao et al<sup>4</sup> concluded in their research that all gallbladder infected with the parasite contained eggs in their stones (incredibly pigmented).

Another study described the relation between *C. Sinensis* infection and developing intra-hepatic stones.<sup>8</sup>

On the other hand, a case report explained that acute cholecystitis occurred in a 68-year-old male patient. He was found to have a necrotising gallbladder without gallstones. The liver flukes were the only aetiology.<sup>9</sup>

Most presentation of the parasitic infection in the gallbladder are mostly asymptomatic or mild. Unfortunately, there is no definitive blood test to diagnose the condition. The patient can present with normal complete blood count and liver function, and carry the liver fluke.

Stool analysis may be a valuable tool to detect eggs in the faeces of an infected patient. Therefore, testing patients who recently travelled or coming from endemic countries can be a good option.

Chronic parasitic infection increases the incidences of the biliary tract and gallbladder malignancy. It was described in the literature in 1900 and 1956 that several predisposing factors may lead to such complication. The increased desquamation in the epithelium and peri-ductal fibrosis is directly related to the presence of the parasite, leading to the formation of carcinoma.<sup>10</sup>

On the other hand, due to the high concentration of bile in the gallbladder, which increases the rate of worm death, gallbladder cancer is rare. It is also rare due to the type of stones developed because of the presence of the parasite, which is pigmented.<sup>11</sup>

Radiological examinations are essential in detecting the parasite in the biliary tree. Ultrasonography is sensitive to see intra-hepatic dilatation and periductal echogenicity, and floating material in the gallbladder. Computer tomography (CT-scan) and magnetic resonance imaging (MRI) with enhanced dynamic con-

trast can detect the presence and the movement of the parasite.<sup>12</sup>

Management of *C. Sinensis* infected gallbladder is cholecystectomy, followed by drugs to eradicate any ruminant parasite or eggs present. Antibiotics such as triclabendazole, praziquantel, bithionol, albendazole, levamisole, and mebendazole are taken according to protocol. Our patient received albendazole 10 mg/kg/day for 7-days.

## CONCLUSION

*Clonorchis Sinensis* infection is a common presentation in far East and Asian countries. It is exceedingly rare in Middle East countries, especially in Kuwait. However, many patients traveling from and into endemic countries may encounter this parasite. Therefore, listing this disease in our differential is essential to avoid adverse complication and early management.

## INSTITUTIONAL BOARD PERMISSION

Yes.

## CONSENT

The authors have received written informed consent from the patient.

## CONFLICTS OF INTEREST

The authors declare that they have no conflicts of interest.

## REFERENCES

1. Wu W, Qian X, Huang Y, Hong Q. A review of the control of *clonorchiasis sinensis* and *Taenia solium taeniasis/cysticercosis* in China. *Parasitol Res.* 2012; 111(5): 1879-1884. doi: [10.1007/s00436-012-3152-y](https://doi.org/10.1007/s00436-012-3152-y)
2. Rohela M, Johari S, Jamaiah I, Init I, Lee SH. Acute cholecystitis caused by *Clonorchis sinensis*. *Southeast Asian J Trop Med Public Health.* 2006; 37(4): 648-651.
3. Hong ST, Fang Y. *Clonorchis sinensis* and clonorchiasis, an update. *Parasitol Int.* 2012; 61(1): 17-24. doi: [10.1016/j.parint.2011.06.007](https://doi.org/10.1016/j.parint.2011.06.007)
4. Qiao T, Ma RH, Luo XB, Luo ZL, Zheng PM. Cholecystolithiasis is associated with *Clonorchis sinensis* infection. *PLoS One.* 2012; 7(8): e42471. doi: [10.1371/journal.pone.0042471](https://doi.org/10.1371/journal.pone.0042471)
5. Shin HR, Oh JK, Masuyer E, Curado MP, Bouvard V, Fang YY, et al. Epidemiology of cholangiocarcinoma: an update focusing on risk factors. *Cancer Sci.* 2010; 101(3): 579-585. doi: [10.1111/j.1349-7006.2009.01458.x](https://doi.org/10.1111/j.1349-7006.2009.01458.x)
6. Stunell H, Buckley O, Geoghegan T, Torreggiani WC. Recurrent pyogenic cholangitis due to chronic infestation with *Clonorchis sinensis* (2006: 8b). *Eur Radiol.* 2006; 16(11): 2612-2614. doi: [10.1007/s00330-006-0354-7](https://doi.org/10.1007/s00330-006-0354-7)
7. Al-Karawi MA, Qattan N. *Clonorchis sinensis*: A case report. *Ann Saudi Med.* 1992; 12(1): 93-95. doi: [10.5144/0256-4947.1992.93](https://doi.org/10.5144/0256-4947.1992.93)
8. Choi D, Lim JH, Lee KT, Lee JK, Choi SH, Heo JS, et al. Gallstones and *Clonorchis sinensis* infection: a hospital-based case-control study in Korea. *J Gastroenterol Hepatol.* 2008; 23(8 Pt 2): e399-404. doi: [10.1111/j.1440-1746.2007.05242.x](https://doi.org/10.1111/j.1440-1746.2007.05242.x)
9. Oh JT, Kang DB, Jo HJ. Acute cholecystitis associated with *Clonorchis sinensis* infection. *Ann Surg Treat Res.* 2014; 87(2): 104-107. doi: [10.4174/astr.2014.87.2.104](https://doi.org/10.4174/astr.2014.87.2.104)
10. Hou PC. The relationship between primary carcinoma of the liver and infestation with *Clonorchis sinensis*. *J Pathol Bacteriol.* 1956; 72(1): 239-246. doi: [10.1002/path.1700720130](https://doi.org/10.1002/path.1700720130)
11. Tio TL. Endosonography in gastroenterology. Berlin, Germany: Springer Science & Business Media; 2012.
12. Choi D, Hong ST. Imaging diagnosis of clonorchiasis. *Korean J Parasitol.* 2007; 45(2): 77-85. doi: [10.3347/kjp.2007.45.2.77](https://doi.org/10.3347/kjp.2007.45.2.77)