

Case Report

*Corresponding author

Mustafa Celik, PhD

Physician

Department of Otolaryngology

Head and Neck Surgery

Bakırköy Dr. Sadi Konuk Training and
Research Hospital

Zuhuratbaba Mah. Tevfik Sağlık Cad.

No: 11, Bakırköy

Istanbul, Turkey

Tel. 0905335976636

E-mail: dr.mcelik@yahoo.com

Volume 2 : Issue 1

Article Ref. #: 1000OTLOJ2108

Article History

Received: January 6th, 2016

Accepted: January 18th, 2016

Published: January 19th, 2016

Citation

Yegin Y, Celik M, Elbistanlı MS, Kayhan FT. An unusual entity of sarcoidosis: acute parotitis. *Otolaryngol Open J.* 2016; 2(1): 28-30. doi: [10.17140/OTLOJ-2-108](https://doi.org/10.17140/OTLOJ-2-108)

Copyright

©2016 Celik M. This is an open access article distributed under the Creative Commons Attribution 4.0 International License (CC BY 4.0), which permits unrestricted use, distribution, and reproduction in any medium, provided the original work is properly cited.

An Unusual Entity of Sarcoidosis: Acute Parotitis

Yakup Yegin, MD; Mustafa Celik, MD*; Mustafa Suphi Elbistanlı, MD; Fatma Tülin Kayhan, MD

Department of Otolaryngology, Head and Neck Surgery, Bakırköy Dr. Sadi Konuk Training and Research Hospital, Istanbul, Turkey

ABSTRACT

Sarcoidosis is a rare systemic granulomatous disease of unknown etiology that may affect many organ and system, mainly lungs. This disease is rare in children. Sarcoidosis is staging contingent on posterior-anterior chest x-ray. Stage III rarely occurs. In generally, sarcoidosis in children is diagnosed by extrapulmonary organ involvement. We presented hereby a rare case of sarcoidosis stage III diagnosed in a child patient with acute parotitis and reviewed the relevant literature.

KEY WORDS: Sarcoidosis; Acute parotitis; Staging; Child; Granulomatous; Chest X-ray.

INTRODUCTION

Sarcoidosis is a rare systemic granulomatous disease of unknown etiology that may affect many organs and system, mainly lungs and rarely affects child.¹ The diagnosis of sarcoidosis is more difficult because of its rarity and the similarity to other several granulomatous diseases.^{2,3} There are four stages in sarcoidosis based on the extent of lung involvement. These stages are: stage 0 (normal); stage I (Bilateral Hilar Adenopathy (BHL) without pulmonary infiltrates); stage II (BHL plus pulmonary infiltrates); stage III (parenchymal infiltrates without BHL) and stage IV (irreversible scarring and distortion). Stage I and stage II are the most common types of presentation.^{3,4} Hereby, we report a rare case of sarcoidosis stage III diagnosed in a child patient with acute parotitis and reviewed the relevant literature.

CASE REPORT

A 12-year-old male presented with a 3-day history of painful, tenderness, swelling on right preaurikuler and submandibular area. The patient's history was clear from trauma, frequent infection and mumps. Tenderness and hyperemia of the skin on preaurikuler and submandibular area was observed. Further, otolaryngological and systemic examinations were unremarkable. Complete Blood Count (CBC), biochemistry, C-reactive protein (CRP) and coagulometer tests were applied. The patient's White Blood Count (WBC) 15,000 /mm³ (N:4,000-11,000/mm³), CRP:15, 2 mg/dl (N:0-1.0 mg/dl), amylase 128 mg/dl (N:10-100 mg/dl). All other laboratory test results were unremarkable. The ultrasonography on neck revealed the presence of servical multiple tender, elliptic configuration lymphadenopathy with mild pallor that the largest of measuring approximately 30×17 mm. The patient was diagnosed with acute parotitis. We prescribed amoxicillin-clavulanic acid (40 mg/kg/day) 2×1 for two weeks. We reassessed the patient after medical therapy. The treatment regimen applied was prolonged with two weeks because of persisting of patient's complaints. Even though, the persisting of patient's complaints was observed, so patient was evaluated in more details. Vasculitis panel, including Anti-nuclear antibody (ANA), Antineutrophil cytoplasmic antibody (c-ANCA), perinuclear neutrophil antibodies (p-ANCA), Radio frequency (RF), chest x-ray and tuberculosis skin test Purified Protein Derivative (PPD) were applied. Vasculitis panel was within normal limits and his tuberculosis skin test revealed the presence of a skin reaction of 4 mm. There was no family history of tuberculosis. Chest x-ray revealed the presence of ground glass view on

superior segment of the right lung. (Figure 1) High Resolution Computer Tomography (HRCT) was applied to evaluate lung parenchyma and it revealed the presence of patchy, ground glass view and air trapping with no enlarged hilar lymph nodes and a normal mediastinal silhouette on superior segment superior and apical segment of the right lung. (Figure 2) Fine needle aspiration biopsy was performed from cervical lymphadenopathy. Biopsy revealed the presence of non-necrotising epithelioid cell granulomas with giant cells. The patient was suspect of granulomatous diseases especially sarcoidosis. Angiotensin Converting Enzyme (ACE) was 128.7 U/L (normal: 8-52 U/L). Based on these findings, sarcoidosis stage III was diagnosed and the patient was prescribed oral prednisolone 2 mg/kg/day. The severity of his symptoms decreased following treatment and he was symptom-free at his 2-year follow-up and prednisolone dose was reduced to 2 mg/day. His medical therapy including prednisolone is still proceeding.

and system, is characterized by a variable clinic presentation and course.^{1,2} Even though it occurs more frequently at 20-40 years, it can occur at any age. It relatively occurs rare in childhood.³ In pediatric population, sarcoidosis is usually characterized by two clinic presentation. One of them, it is characterized by triad of rash, arthritis and eye involvement, occurs frequently in young children. Other clinic presentation, older children present with involvement of the lungs, lymph nodes and eyes as adult.^{3,4}

Sarcoidosis may often affect lungs more than 90% of patients, sometimes with symptoms or asymptomatic radiographic abnormalities.^{1,2} The radiographic abnormalities consist of bilateral hilar adenopathy, diffuse or local pulmonary infiltrates, irreversible scarring and distortion. However, clinic presentations and radiographic findings can be not similar. The chest x-ray was categorized into four stages by Scadding, but these stages are not necessarily denote the severity or progression of disease.³ According these stages, normal chest x-ray is stage 0, bilateral hilar adenopathy, often with right paratracheal adenopathy, without pulmonary infiltrates is stage 1, bilateral hilar adenopathy with parenchymal infiltration is stage II, parenchymal infiltration without hilar adenopathy is stage III and advanced parenchymal disease demonstrating fibrosis is stage 4.^{3,4} The most common of these stages are stage 1 and 2.⁴ In our case, stage III lung involvement, is rarely reported in literature was determined according to these staging.

Sarcoidosis can affect minor and major salivary glands, mainly parotid gland, approximately 6% of patients.⁵⁻⁸ Parotid gland affecting cause variable clinic presentation between acute parotitis and diffuse parotid enlargement due to chronic inflammation. It can cause sicca like-symptom in patients. In our case, acute parotitis was determined but there were no any sicca like-symptoms as extrapulmonary involvement. In literature, this clinic presentation was reported in rare.¹

Sarcoidosis is diagnosed by a correlation between clinical and radiographic findings supported by histopathological examination. However, there are no specific laboratory tests for diagnosis of sarcoidosis but some abnormalities in laboratory tests can be determined such as elevated erythrocyte sedimentation rate and other acute phase reactants, anemia, leukopenia and hypergammaglobulinemia.¹⁻³ Even though serum ACE levels are elevated in more 40% patients with sarcoidosis, the value of a serum ACE level for diagnosis of sarcoidosis remains limited.^{1,9} In our case, abnormalities in laboratory tests were elevated ACE and acute phase reactants.

The differential diagnosis of sarcoidosis consist of granulomatous disease such as tuberculosis, lymphoma, parasitic infections.^{3,4,10}

The treatment of sarcoidosis depends on its severity but typically includes prednisolone and other immunosuppressive drugs, especially methotrexate. However, medical therapy is not mandated for sarcoidosis because of regression spontaneously.^{3,6,8} In our case, patient was treated by prednisolone 2 mg/

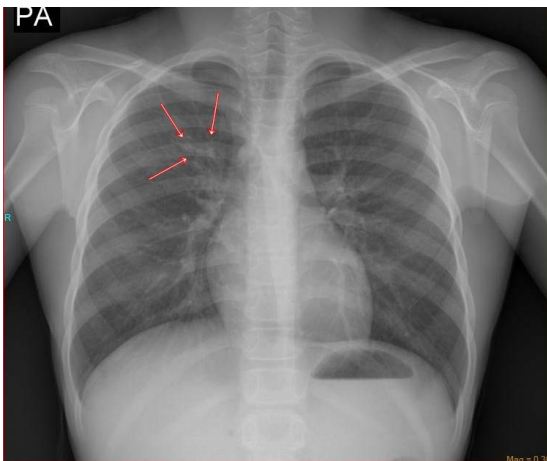


Figure 1: Chest X-ray showing the presence of ground glass view on superior segment of the right lung (red arrows).

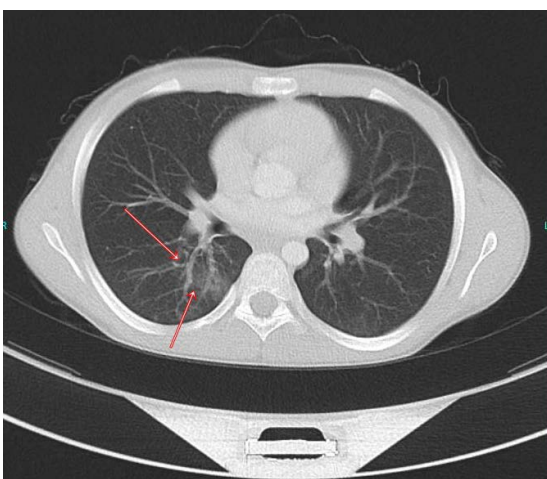


Figure 2: Axial view of HRCT image showing the presence of patchy, ground glass view and air trapping with no enlarged hilar lymph nodes and a normal mediastinal silhouette on superior segment superior and apical segment of the right lung. (red arrows).

DISCUSSION

Sarcoidosis is a rare autoimmune systemic granulomatous disease of unknown etiology that may effect many organ

kg/day in a 2 years and the severity of his symptoms decreased following treatment, prednisolone dose was reduced to 2 mg/day.

CONCLUSION

Sarcoidosis should be considered in the differential diagnosis of patients with acute parotitis in children. A high degree of clinical suspicion is needed to determine this rare potential etiology. Because patients with sarcoidosis can present with many different manifestations affecting multiple systems, the otolaryngologist must be aware of sarcoidosis and its rare presentations.

CONSENT

Written informed consent was obtained from the patient described in this case.

CONFLICTS OF INTEREST

The authors declare that they have no conflicts of interest.

FINANCIAL DISCLOSURE

The authors declare that this case has received no financial support.

REFERENCES

1. Azad C, Arya A, Mahajan V, Goyal S. An atypical case of parotid gland swelling and arthritis in a child. *Indian J Pediatr.* 2014; 51(8): 662-663.

2. Shetty AK, Gedalia A. Childhood sarcoidosis: a rare but fascinating disorder. *Pediatr Rheumatol on line J.* 2008; 23(6): 16. doi: [10.1186/1546-0096-6-16](https://doi.org/10.1186/1546-0096-6-16)

3. Gokdemir Y, Ersu R, Karadag B, et al. An unusual case of childhood sarcoidosis: an unusual clinical case. *Arch Argent Pediatr.* 2013; 111(5): 441-445.

4. Cemlyn-Jones J, Gamboa F, Teixeira L, et al. Sarcoidosis: a less common presentation. *Rev Port Pneumol.* 2009; 15(3): 543-552.

5. James DG, Sharma OP. Parotid gland sarcoidosis. *Sarcoidosis Vasc Diffuse Lung Dis.* 2000; 17: 27-32.

6. White ES, Lynch JP 3rd. Current and emerging strategies for the management of sarcoidosis. *Expert Opin Pharmacother.* 2007; 8: 1293-1311. doi: [10.1517/14656566.8.9.1293](https://doi.org/10.1517/14656566.8.9.1293)

7. Yanardag H, Pamuk ON, Uygun S, et al. Sarcoidosis: child vs adult. *Indian J Pediatr.* 2006; 73: 143-145.

8. Milman N, Hoffmann AL. Childhood sarcoidosis: long-term follow-up. *Eur Respir J.* 2008; 31: 592-598. doi: [10.1183/09031936.00011507](https://doi.org/10.1183/09031936.00011507)

9. El Sayed F, Torbey G, Youssef H, Chababi M. Childhood sarcoidosis: diagnostic issues. *Dermatol Online J.* 2013; 19(10): 20037.

10. Lee JH, Lim YJ, Lee S, et al. Early onset childhood sarcoidosis with incidental multiple enchondromatosis. *J Korean Med Sci.* 2012; 27(1): 96-100. doi: [10.3346/jkms.2012.27.1.96](https://doi.org/10.3346/jkms.2012.27.1.96)