

Letter to the Editor

***Corresponding author**

Arpit Saxena, MS (ENT)

Department of ENT
Uttar Pradesh University of
Medical Sciences
Saifai, Etawah
UP 206130, India
Tel. +91 9532306179
E-mail: arpitsaxenaexam@gmail.com

Volume 3 : Issue 3

Article Ref. #: 1000OTLOJ3140

Article History

Received: June 14th, 2017

Accepted: June 19th, 2017

Published: June 21st, 2017

Citation

Saxena A. Chronic otitis media with facial palsy: An unexpected etiology. *Otolaryngol Open J.* 2017; 3(3): 41-42. doi: [10.17140/OTLOJ-3-140](https://doi.org/10.17140/OTLOJ-3-140)

Copyright

©2017 Saxena A. This is an open access article distributed under the Creative Commons Attribution 4.0 International License (CC BY 4.0), which permits unrestricted use, distribution, and reproduction in any medium, provided the original work is properly cited.

Chronic Otitis Media with Facial Palsy: An Unexpected Etiology

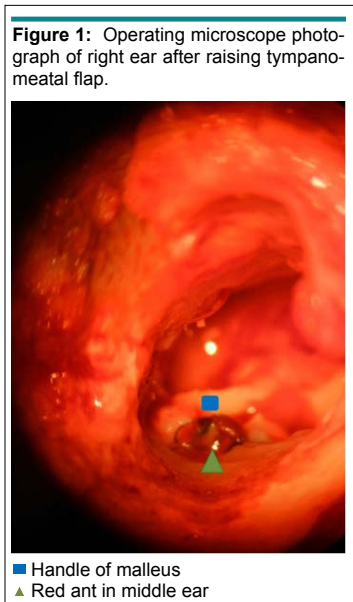
Arpit Saxena, MS (ENT)^{1*}; Dharmendra Kumar Singh, MS (ENT)²; Vivek Raj Sinha, MS (ENT)²

¹Department of ENT, Uttar Pradesh University of Medical Sciences, Saifai, Etawah, UP, India

²Department of ENT, Command Hospital (Central Command), Lucknow, UP, India

Chronic otitis media is a commonly observed disease worldwide. Facial palsy in a patient can be attributed to many causes. Facial paresis with chronic otitis media is almost always attributable to facial palsy. This article reports the clinical condition of a patient in whom the etiology of facial paresis was not conventional. However, the unexpected etiology that was observed could not be located in any pre-existing literature related to facial paresis.

A 13-year-old female, student by occupation presented with a medical history of severe right sided otalgia for 6 days and facial asymmetry for 4 days. Only 6 months earlier, she had discharge from her right ear. There was no history of skin rashes over the ear or face or facial asymmetry. Otological examination indicated an edematous external auditory canal, moderate central perforation in the tympanic membrane with granulation tissue in the antero-superior quadrant. Right sided lower motor neuron facial palsy was classified as House-Brackmann grade IV. The tuning fork test demonstrated right side conductive deafness in the affected patient. Routine hematological and biochemical parameters which were analyzed indicated normal values of measurement. Her chest X-ray report was normal and she tested negative for human immunodeficiency virus (HIV). Contrast enhanced computed tomography (CT) scan showed soft tissue density in the middle ear and the mastoid air cells. On the basis of the clinical and radiological findings, it was earlier diagnosed as otitis media induced facial paresis. Thus, tympanomastoid exploration was accordingly planned. After the surgery was being performed, the granulation tissue was seen filling the middle ear. While performing cortical mastoidectomy, a dead red ant (solenopsis) was observed in the middle ear, which was carefully removed (Figure 1). The granulation tissue over the promontory and the horizontal portion of the facial nerve was removed. The ear ossicles were intact and underlay tympanoplasty was the implemented procedure. Post-operatively she received dose of oral steroids, which was tapered in 3 weeks and her facial palsy resolved completely within 4 months.



Pradhan et al¹ demonstrates that foreign bodies may lead to facial paresis. Zamzil et al² have reported facial palsy due to the presence of an intraural tick. In the present case, the red ant possibly entered through the pre-existing perforation in the tympanic membrane and inoculated its venom into the middle ear. The presence of the toxin and the dead ant in the middle ear probably led to the formation of the granulation tissue. Facial paresis may have thus been due to the effect of the venom that would have entered the fallopian canal by natural dehiscence. Therefore, the discussed case of the young female having chronic otitis media with facial paresis due to the presence of an insect in the middle ear cleft helps to expand the horizon of unusual etiology of facial paresis.

CONFLICTS OF INTEREST

The authors declare that they have no conflicts of interest.

SOURCE(S) OF SUPPORT: None.

REFERENCES

1. Pradhan SK, Gupta S. Migrated aural foreign body in parapharyngeal space. *Indian J Otol.* 2016; 22: 66-69. doi: [10.4103/0971-7749.176501](https://doi.org/10.4103/0971-7749.176501)
2. Zamzil AA, Baharudin A, Shahid H, Din Suhaimi S, Nor Affendie MJ. Isolated facial palsy due to intra-aural tick (ixodoidea) infestation. *Arch Orofacial Sciences.* 2007; 2: 51-53. Web site. http://www.kck.usm.my/ppsg/aos/Vol_2/5153_Bahar_Tick.pdf. Accessed June 13, 2017.