

Letter to the Editor

Endoscopic Treatment of Refractory Variceal Bleed

Shreyas Saligram, MD, MRCP, FACP, FASGE^{1*}; Marina Roytman, MD, FACP¹; Helen Wong, MD²; Thimmaiah Theethira, MD, DM¹

¹Department of Gastroenterology, Hepatology & Nutrition, 2823 Fresno Street, Fresno, CA 93721, USA

²VA Central California Health systems, 2615 E Clinton Ave, Fresno, CA 93703, USA

*Corresponding author

Shreyas Saligram MD, MRCP, FACP, FASGE

Chief of Gastroenterology, Hepatology and Nutrition, Department of Gastroenterology, Hepatology and Nutrition, University of California San Francisco, Fresno, CA, USA; E-mail: drsaligram@yahoo.com

Article information

Received: February 19th, 2019; **Revised:** April 1st, 2019; **Accepted:** April 3rd, 2019; **Published:** May 9th, 2019

Cite this article

Saligram S, Roytman M, Wong H, Theethira T. Endoscopic treatment of refractory variceal bleed. *Gastro Open J.* 2019; 4(1): 1-3. doi: [10.17140/GOJ-4-128](https://doi.org/10.17140/GOJ-4-128)

A 70-year-old man with history of end-stage liver disease due to alcohol misuse disorder was admitted to the hospital with hematemesis. He had at least 5 episodes of bright red hematemesis and was feeling dizzy. He complained of epigastric pain for 3 days prior to presentation. He had noticed progressive development of dark urine, pale stools and yellow sclera. He had not consumed any non-steroidal anti-inflammatory drugs recently.

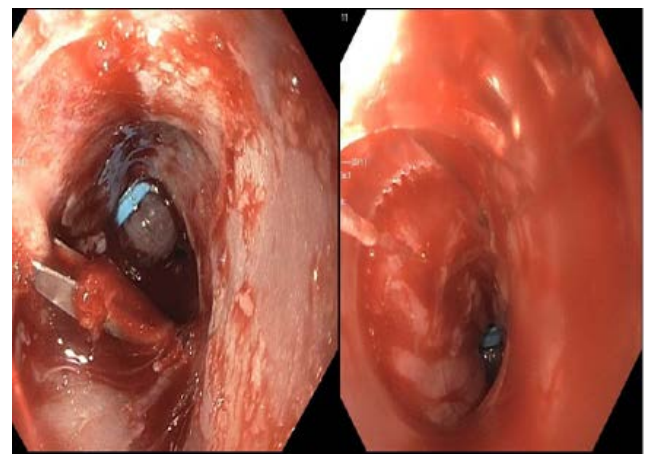
His last consumption of alcohol was 3 months ago. He had a prior history of gastrointestinal (GI) bleeding and had undergone upper GI endoscopy that revealed large varices with high-risk stigmata (white nipple sign) requiring variceal band ligation. His last endoscopy was 6 weeks prior to presentation. He was non-compliant with prophylactic propranolol and was not on any other medications.

On physical examination, patient appeared chronically ill, pale with evidence of scleral icterus and spider nevi. He was alert and in apparent discomfort due to recent vomiting and retching. His BP was 90/50 mmHg with a pulse of 110/minute. He was afebrile. Pertinent laboratory studies revealed hemoglobin of 6 g/dL, platelets of 40,000 μ L and INR of 2.2. His model for end-stage liver disease (MELD)-Na was calculated to be 25.

He was intubated and was transfused with 1 unit of blood, 1 unit of platelets and fresh frozen plasma. He was initially treated with intravenous proton pump inhibitors, Octreotide and Ceftriaxone antibiotics. He underwent emergent upper GI endoscopy. It revealed 4 large varices with high-risk stigmata for recent bleeding (red wale sign in the distal esophagus) and significant amount of prior scar tissue. There was no evidence of gastric varices. Decision was made to proceed with variceal band ligation to prevent further bleeding. At least 4 bands were placed, however some of the bands slipped immediately due to scarring from prior band-

ing and there was sudden hemorrhaging from the varices (Figure 1). Patient became more hypotensive with the blood pressure of 70/30 mmHg requiring initiation of vasopressors.

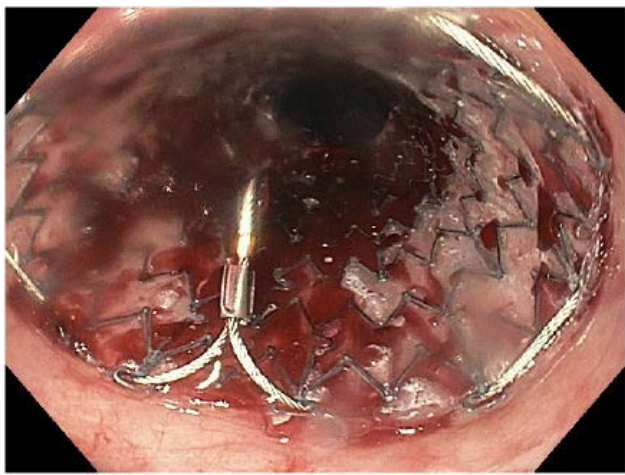
Figure 1. Active Hemorrhage Despite Endoscopic Therapy



His MELD was more than 18 and he was therefore a relative contraindication for transjugular intrahepatic portosystemic shunt (TIPS). Decision was therefore made to tamponade the varices with an esophageal stent. A guidewire was placed into the stomach by upper GI endoscopy. The endoscope was then removed and a fully covered 23 mm \times 15 cm long, fully covered metal stent was introduced over the guidewire. This was followed by upper GI endoscopy. The gastroesophageal junction (GEJ) was noted to be at 40 cm. The distal end of the stent was placed 3 cm across the GEJ under direct visualization and proximal end at 28 cm of esophagus without the aid of fluoroscopy and under direct endoscopic visualization. Immediate tamponade of bleeding varices were noted (Figure 2). The patient was monitored for another 2 days in the hospital and remained stable without signs of recurrent

bleeding, need for transfusions or hemodynamic instability. He was discharged home with twice a day high dose proton pump inhibitor to prevent acid reflux from the stent. Repeat upper GI endoscopy was performed 2 weeks later on the outpatient basis. Rat-tooth forceps was used to remove the esophageal stent. The endoscopy revealed 4 columns of large varices. The varices were then ligated by 4 bands to prevent future bleeding. He was followed regularly for another 3 months and had no further GI bleed and is doing well.

Figure 2. Stent Resulting in Hemostasis of Acute Variceal Bleed



DISCUSSION

Cirrhosis of liver can be complicated by esophageal varices.¹ A bleeding esophageal varices can cause significant mortality and morbidity. The risk of recurrent GI bleed is very high if not treated. Endoscopic management along with pharmacotherapy is the current standard of care for management of esophageal varices. Bands placed through endoscopy can cause scarring of these varices and ligate it thereby preventing GI bleed. Bands can be placed either as a primary prophylaxis in large varices that have never bled before or as secondary prophylaxis in patients with history of bleed or who have high-risk features for bleeding such as nipple sign or red wale sign of varices. Banding of varices is highly successful in most cases. In minority of cases with repeated prior banding, scar formation will prevent successful band ligation. If this happens in the setting of acute GI bleed, the mortality is very high. The society practice guidelines suggest using a Minnesota tube, which is an esophageal balloon for immediate tamponade to control bleeding in refractory variceal bleed.² This can be in place for 24 hours and subsequently patients undergo TIPS.

Placement of a Minnesota tube is a complex procedure and can be cumbersome when needed acutely. It has a success rate of only 50% in controlling GI bleed and can have certain risks like mal-deployment and esophageal perforation especially if the gastric balloon is inflated in esophagus.¹ A multicenter randomized control trial of esophageal balloon tamponade *vs* stent in control of refractory variceal GI bleed showed that success was higher

in stent group *vs* balloon group (66% *vs* 20%), control of bleeding was higher in stent group (85% *vs* 47%), Adverse events were lower in the stent group (15% *vs* 47%) and TIPS was used more frequently in the balloon group (4 *vs* 10).³

The TIPS is contraindicated in patients with right heart failure, pulmonary hypertension, severe renal failure, uncorrected coagulopathy, prior history of encephalopathy and high MELD.⁴ TIPS, although is very effective in controlling variceal bleed, has some risks. About a third of patients can experience a debilitating encephalopathy even in patients without prior history of it.⁴ Other risks are liver laceration, hematoma and procedure-related death.⁴ Besides patients who undergo TIPS should be regularly followed with ultrasound of abdomen to evaluate its patency.

Self-expanding fully covered metal esophageal stents have been traditionally used for treatment of malignant esophageal strictures and esophageal perforation. The stent's large diameter and exact approximation to the lumen and mucosa of esophagus makes it very effective in treatment of refractory GI bleed either from varices or diffuse oozing from mucositis.³ The ease of placing and removing the stent under direct visualization without the aid of fluoroscopy makes it safer than Minnesota tube.⁵ Esophageal stents can have certain risks such as stent migration, which can be up to 30% of cases. This complication usually occurs after few days and the migrated stent is easily retrievable. The tamponade that is achieved in the initial 24-48 hours is crucial to controlling the hemorrhage which otherwise can be life-threatening. Other risks of esophageal stent are acid reflux, which can cause aspiration and this can be minimized by high doses of twice a day proton pump inhibitors. Stent-related esophageal perforation is very rare in expert hands, especially if caution is taken to ensure that guidewire is placed in the stomach. A recent meta-analysis of 155 patients from 12 studies showed success rate of achieving hemostasis within 24 hours in acute variceal bleed was 96%. The adverse events included rebleeding, ulceration and stent migration in 36% of patients. The 60 day survival rate was 64% in those undergoing the procedure.⁶ Another meta-analysis of 80 patients from five studies showed success rate of 94% with no stent-related mortality. Number of patients with uncontrolled bleeding despite the stent placement was 12%, 21% of patients had stent migration and 34% died due to liver disease related cases.⁷ We have described the technique of placement of Self-expanding fully covered metal esophageal stents under endoscopic guidance for treatment of refractory variceal bleed. However, some of the other kinds of stents like Denis Ella stent used in Europe for treatment of refractory variceal bleed does not need endoscopic visualization for placement of it.

There is a growing body of evidence suggesting that esophageal stents are safe and effective in treatment of refractory variceal bleeding and it should be the standard of care. This method is safer and more effective compared to Minnesota tube in controlling acute hemorrhage from refractory variceal bleed and can be used as either a bridge to TIPS or better as an alternate to TIPS.

CONFLICTS OF INTEREST

The authors declare that they have no conflicts of interest.

REFERENCES

1. Boregowda U, Umapathy C, Halim N, et al. Update on the management of gastrointestinal varices. *World J Gastrointest Pharmacol Ther.* 2019; 10(1): 1-21. doi: [10.4292/wjgpt.v10.i1.1](https://doi.org/10.4292/wjgpt.v10.i1.1)
2. Garcia-Tsao G, Abraldes JG, Berzigotti A, Bosch J. Portal hypertensive bleeding in cirrhosis: Risk stratification, diagnosis, and management: 2016 practice guidance by the American Association for the study of liver diseases. *Hepatology.* 2017; 65(1): 310-335. doi: [10.1002/hep.28906](https://doi.org/10.1002/hep.28906)
3. Escorsell À, Pavel O, Cárdenas A, et al. Esophageal balloon tamponade versus esophageal stent in controlling acute refractory variceal bleeding: A multicenter randomized, controlled trial. *Hepatology.* 2016;63(6): 1957-1967. doi: [10.1002/hep.28360](https://doi.org/10.1002/hep.28360)
4. Fagioli S, Bruno R, Venon DW, et al. Consensus conference on TIPS management: Techniques, indications, contraindications. *Dig Liver Dis.* 2017; 49(2): 121-137. doi: [10.1016/j.dld.2016.10.011](https://doi.org/10.1016/j.dld.2016.10.011)
5. Saligram S, Lim D, Pena L, Friedman M, Harris C, Klapman J. Safety and feasibility of esophageal self-expandable metal stent placement without the aid of fluoroscopy. *Dis Esophagus.* 2017; 30(8): 1-6. doi: [10.1093/dote/dox030](https://doi.org/10.1093/dote/dox030)
6. McCarty TR, Njei B. Self-expanding metal stents for acute refractory esophageal variceal bleeding: A systematic review and meta-analysis. *Dig Endosc.* 2016; 28(5): 539-547. doi: [10.1111/den.12626](https://doi.org/10.1111/den.12626)
7. Shao XD, Qi XS, Guo XZ. Esophageal stent for refractory variceal bleeding: A systemic review and meta-analysis. *Biomed Res Int.* 2016; 2016: 4054513. doi: [10.1155/2016/4054513](https://doi.org/10.1155/2016/4054513)