

Case Report

Corresponding author

Yuko Kobashi, MD
Department of Radiology
Tokyo Dental College
Ichikawa General Hospital
5-11-13, Sugao, Ichikawa
Chiba, 271-8513 Japan
Tel. +81-47-322-0151
Fax: +81-47-325-4456
E-mail: ykobashi@jikei.ac.jp

Volume 1 : Issue 6

Article Ref. #: 1000SEMOJ1130

Article History

Received: March 16th, 2016

Accepted: March 29th, 2016

Published: March 30th, 2016

Citation

Kobashi Y, Suzuki T, Tazawa Y, et al. Iliopsoas tendon injury in an adolescent: a case report. *Sport Exerc Med Open J.* 2016; 1(6): 198-200. doi: [10.17140/SEMOJ-1-130](https://doi.org/10.17140/SEMOJ-1-130)

Copyright

©2016 Kobashi Y. This is an open access article distributed under the Creative Commons Attribution 4.0 International License (CC BY 4.0), which permits unrestricted use, distribution, and reproduction in any medium, provided the original work is properly cited.

Iliopsoas Tendon Injury In an Adolescent: A Case Report

Yuko Kobashi, MD^{1*}; Takuya Suzuki, MD²; Yoko Tazawa, MD²; Yohei Munetomo, MD¹; Akira Baba, MD¹; Sinji Yamazoe, MD¹; Takuji Mogami, MD¹

¹Department of Radiology, Tokyo Dental College, Ichikawa General Hospital, 5-11-13, Sugao, Ichikawa, Chiba, 271-8513, Japan

²Department of Radiology, Fujisawa Shonandai Hospital, Kanagawa Prefecture 252-0802, Fujisawa, Japan

ABSTRACT

Background: The Iliopsoas tendon injuries are generally considered uncommon. Especially in children and adolescents, the iliopsoas injury usually occurs in conjunction with avulsion of the lesser trochanter. We reported a rare case of a partial tear of the left psoas major tendon in an adolescent patient.

Case Report: A 14-year-old-male who had a left inguinal pain came to our hospital for consultation. The injury occurred earlier when he was playing a basketball game he turned on a pivot and he suddenly felt left inguinal pain. As a result of the sudden pain caused by the movement he could not move his left hip joint by himself. Neurological examination revealed no motor or sensory deficits with normal reflexes. On the MRI, the left psoas major tendon showed up as swollen and was separated from the left iliacus tendon when compared to the right side. The left psoas major tendon and myotendinous junction showed high signal intensity suggestive of a partial tear on STIR axial image. The lesser trochanter showed slightly high signal intensity when compared to the opposite side but showed no evidence of an avulsion fracture.

Conclusion: The Iliopsoas tendon injuries without lesser trochanteric avulsion in children and adolescents are distinctly uncommon. There is an estimated prevalence of 0.66%. In future we would suggest, we need to evaluate both the lesser trochanter and the insertion of the iliopsoas tendon to rule out lesser trochanter avulsion on the MRI.

KEYWORDS: Iliopsoas muscle; Lesser trochanter; Magnetic Resonance Imaging (MRI).

INTRODUCTION

The iliopsoas tendon acts a thigh flexor and aids in lateral rotation of the hip. The Iliopsoas injuries are generally considered uncommon. Especially, in children and adolescents, the Iliopsoas injury usually occurs in conjunction with avulsion of the lesser trochanter.¹ We report a rare case of a partial tear of the left psoas major tendon in an adolescent patient. The authors obtain written informed consent from the patient for submission of this manuscript for publication.

CASE REPORT

A 14-year-old-male who had a left inguinal pain came to our hospital for consultation. The injury occurred when he was earlier playing a basketball game and turned on a pivot, he suddenly felt left inguinal pain. He is 170 cm tall; 50 kg in weight and has no history of trauma or disease. He has been playing basketball for 5 years at school and plays it for 4 hours every day. On physical examination, there was severe tenderness present in the left inguinal region. Also, there was no erythema. He could not move his left hip joint by himself. Neurological examination revealed no motor or sensory deficits with normal reflexes. The laboratory findings were normal. Hip radiograph showed no abnormality (Figure 1). On MRI, the left psoas major

tendon showed up as swollen and was separated from the left iliacus tendon on STIR axial image when compared to the right side (Figure 2). It shows high signal intensity in that area suggestive of hematoma, this is shown between the psoas major muscle and iliacus muscle (Figures 2 and 3). The left psoas major tendon and myotendinous junction showed high signal intensity on STIR coronal image (Figures 3 and 4). In addition, a partial tear of the left psoas major tendon was visualized (Figures 3 and 4). However, the left lesser trochanter and insertion of the left iliopsoas tendon was maintained (Figure 5). The lesser trochanter showed slightly high signal intensity as compared to the opposite side but showed no evidence of avulsion fracture on STIR axial image (Figure 5).

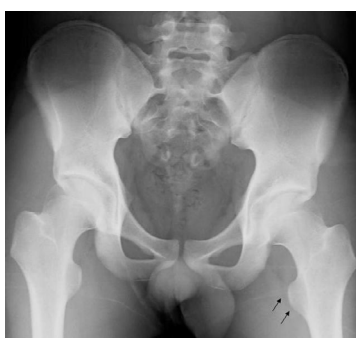

Figure 1: Antero-posterior view of Hip radiograph. There is no evidence of bone fracture in the left lesser trochanter (arrows).

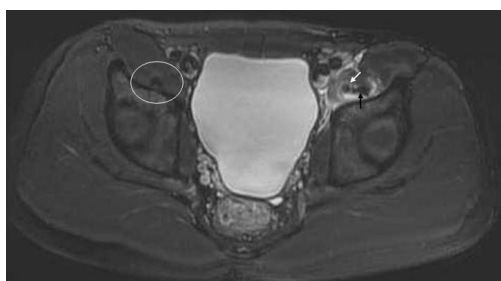


Figure 2: STIR axial hips MRI at level of acetabulums. As compared to the right iliopsoas tendon (white circle), the left psoas major tendon (white arrow) showed swollen and was separated from the left iliacus tendon (black arrow). High signal intensity area suggestive of hematoma is visualized mainly around the left psoas major muscle.

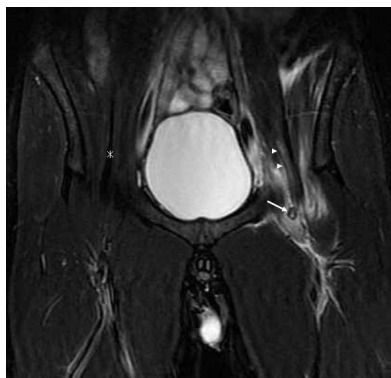

Figure 3: STIR coronal hips MRI at level of pubic symphysis. Both the left psoas major tendon (white arrow) and myotendinous junction (arrowheads) show partial high signal intensity suggestive of tear. The right psoas major tendon (asterisk) is normal.

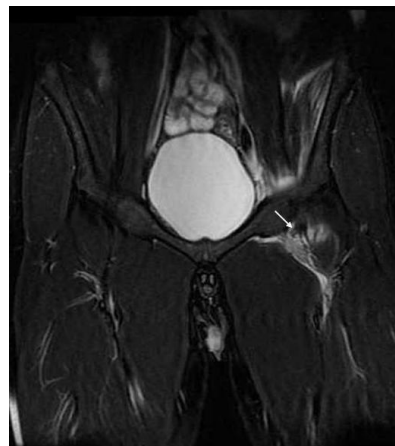


Figure 4: STIR coronal hips MRI at level of pubic symphysis at level of the 4 mm behind from Figure 3. The partial tear of the left psoas major tendon is visualized (white arrow). High signal intensity hematoma is along the left psoas major tendon.

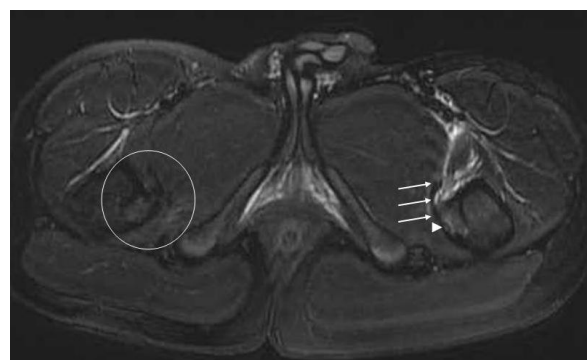


Figure 5: STIR axial hips MRI at level of both lesser trochanters. Both the left lesser trochanter (arrowhead) shows faint high signal intensity but shows no avulsion fracture. The insertion of the iliopsoas tendon (arrow) is the same signal and form as the right side (white circle).

We diagnosed a partial tear of the left psoas major myotendinous junction and tendon due to overuse. He was hospitalized and underwent a conservative therapy. He was discharged after a week with no inguinal pain.

DISCUSSION

The iliopsoas muscle belongs to the inner hip and comprises of a complex of two muscles called psoas major muscle and iliacus muscle. Both muscles pass below the inguinal ligament through the muscular lacuna together and merge at their midpoint to form a common insertion at the lesser trochanter of the femur.¹⁻³ The iliopsoas muscle controls the various actions of postural changes such as walking, running, sitting, or standing. It also keeps the upper body straight while one is performing certain types of exercises in the supine position.^{1,2,4}

The iliopsoas tendon injuries without lesser trochanteric avulsion in children and adolescents are distinctly uncommon, with an estimated prevalence of 0.66%.^{1,2} An even smaller percentage of these injuries occur spontaneously. This is due to the relative weakness of the apophyses compared to the

iliopsoas tendon.^{5,6} Regarding the epiphyseal union of the lesser trochanter, Shama Y et al⁷ reported that age of epiphyseal union of the lesser trochanter was 18-19 in male and women together. Cardoso⁸ reported that the lesser trochanter at age of 14 of male showed nonunion.

In our case, the left lesser trochanter was not fractured but showed faint bone marrow edema. We think the bone marrow edema of the left lesser trochanter occurred as a result of an overload from the left iliopsoas tendon. In addition, we found a partial tear of the left psoas major tendon on MRI. It may be due to the overuse from the patient's sports activity. In adults, isolated fractures of the lesser trochanter are rare but can occur as a result of trauma or sports injuries like jumping, kicking and so on.^{3,4} When iliopsoas muscle and tendon are subjected to a load beyond the strength of the muscle, it occurs. The vast majority of ruptures are partial muscle/tendon tears.^{5,6} Our case is the same as the adults' iliopsoas muscle injuries. Taking a MRI is a good choice to evaluate iliopsoas tendon injuries and distinguishes it from other hip joints diseases. In our case, we could rule out the lesser trochanteric avulsion on MRI.

The iliopsoas muscle/tendon injuries are usually treated conservatively, with rest, physical therapy, and/or anti-inflammatory medications, often with good results.^{1,2}

CONCLUSION

Iliopsoas tendon injuries without lesser trochanter avulsion are uncommon in children and adolescents. We need to evaluate both the lesser trochanter and the insertion of the iliopsoas tendon to rule out lesser trochanter avulsion on MRI. The hips MRI is a good modality for distinguish from them.

CONFLICTS OF INTEREST: None.

CONSENT

The authors obtained written informed consent from the patient for submission of this manuscript for publication.

REFERENCES

1. Bui KL, Sundaram M. Radiologic case study: iliopsoas tendon rupture. *Orthopedics*. 2008; 31(10): pii. Web site. <http://www.healio.com/orthopedics?rID=32083>. Accessed March 15, 2016.
2. Bui KL, Ilaslan H, Recht M, Sundaram M. Iliopsoas injury: an MRI study of patterns and prevalence correlated with clinical findings. *Skeletal Radiol*. 2008; 37(3): 245-249. doi: [10.1007/s00256-007-0414-3](https://doi.org/10.1007/s00256-007-0414-3)
3. DePasse JM, Varner K, Cosculluela P, Incavo S. Atraumatic avulsion of the distal iliopsoas tendon: an unusual cause of hip pain. *Orthopedics*. 2010; 33(8). doi: [10.3928/01477447-20100625-25](https://doi.org/10.3928/01477447-20100625-25)

4. James SL, Davies AM. Atraumatic avulsion of the lesser trochanter as an indicator of tumor infiltration. *Eur Radiol*. 2006; 16(2): 512-514. doi: [10.1007/s00330-005-2675-3](https://doi.org/10.1007/s00330-005-2675-3)

5. Polster JM, Elgabaly M, Lee H, Klika A, Drake R, Barsoum W. MRI and gross anatomy of the iliopsoas tendon complex. *Skeletal Radiol*. 2008; 37(1): 55-58. doi: [10.1007/s00256-007-0393-4](https://doi.org/10.1007/s00256-007-0393-4)

6. Lecouvet FE, Demondion X, Leemrijse T, Vande Berg BC, Devogelaer JP, Malghem J. Spontaneous rupture of the distal iliopsoas tendon: clinical and imaging findings, with anatomic correlations. *Eur Radiol*. 2005; 15(11): 2341-2346. doi: [10.1007/s00330-005-2811-0](https://doi.org/10.1007/s00330-005-2811-0)

7. Sharma Y, Sharma A, Bohra B. Union of epiphyseal centres in pelvis of age group 18-21 years in Rajasthan: A roentgenologic prospective study. *J Indian Acad Forensic Med*. 2013; 35(2): 134-136. Web site. <http://indianjournals.com/IJOR.ASPX?target=ijor:jiafm&volume=35&issue=2&article=010>. Published July 15, 2013. Accessed March 15, 2016.

8. Cardoso HF. Epiphyseal union at the innominate and lower limb in a modern portuguese skeletal sample, and sge estimation in adolescent and young adult male and female skeletons. *Am J Phys Anthropol*. 2008; 135(2): 161-170. doi: [10.1002/ajpa.20717](https://doi.org/10.1002/ajpa.20717)