

## Research

### \*Corresponding author

**Rakesh Bhargava, MBBS, MS**

Professor and Head Department of  
Orthopedics

National Institute of Medical Sciences

Jaipur, RJ 303121, India

E-mail: [drakeshbhargava@hotmail.com](mailto:drakeshbhargava@hotmail.com)

Volume 2 : Issue 1

Article Ref. #: 1000ORTOJ2108

### Article History

Received: November 14<sup>th</sup>, 2016

Accepted: January 25<sup>th</sup>, 2017

Published: January 30<sup>th</sup>, 2017

### Citation

Bhargava R. Muscle pedicle graft  
in avascular necrosis femoral head.  
*Orthop Res Traumatol Open J.*  
2017; 2(1): 29-34. doi: [10.17140/ORTOJ-2-108](https://doi.org/10.17140/ORTOJ-2-108)

### Copyright

©2017 Bhargava R. This is an open access article distributed under the Creative Commons Attribution 4.0 International License (CC BY 4.0), which permits unrestricted use, distribution, and reproduction in any medium, provided the original work is properly cited.

# Muscle Pedicle Graft in Avascular Necrosis Femoral Head

**Rakesh Bhargava, MBBS, MS\***

Professor and Head Department of Orthopedics, National Institute of Medical Sciences,  
Jaipur, RJ 303121, India

## ABSTRACT

**Aims:** To assess the effectiveness of muscle pedicle graft in avascular necrosis (AVN) head femur in Grade 1 and Grade 2 AVN of femoral head grade 1 and grade 2 as head sparing procedure.

**Method:** The pixel count in Tc-99 bone scan single photon emission computed tomography (SPECT) was used as perfusion analysis through a standardized procedure of assessment at six monthly intervals. Comparisons of the scan and the counts at each interval was used to determine whether the procedure was producing a beneficial effect and to what extent. The cases were followed-up for a minimum period of two years.

**Result:** It was discovered that the comparative ratios had a bearing on the clinical improvement and could be used as a predictor variable for the outcome. They also had a significant prognostic value.

**Conclusions:** Muscle pedicle graft in Grade 1 and Grade 2 AVN femoral head does benefit the patient. The SPECT analysis of the Tc-99 bone scan can be used as a monitor and reasonably predict the outcome and adverse end results.

**KEY WORDS:** Single Photon Emission Computed Tomography (SPECT); Muscle pedicle; Vertebra.

**ABBREVIATIONS:** SPECT: Single Photon Emission Computed Tomography; AVN: Avascular necrosis; AP: Anteroposterior; PA: Posteroanterior; THR: Total Hip Replacement.

## INTRODUCTION

Muscle pedicle graft has been advanced as a modality of treatment in Ficat et al<sup>1</sup> Grade 1 and Grade 2 avascular necrosis (AVN) of the head of the femur.<sup>1-3</sup> What effect it has on the vascularity of the head has been a matter of speculation.

This surgery has been performed at our institution since 1983, although there is yet to be a validated method to quantify the blood supply to the diseased head. A constant search for some method by which the blood supply in the diseased head could be quantitatively estimated was sought. The one investigation which seemed to hold out promise was the Tc-99 bone scan.<sup>4</sup> A paper on perfusion studies by Urologists to study renal perfusion in transplanted kidneys drew attention.<sup>5,6</sup> Could the use of radio-isotope Tc-99 and SPECT analysis (Single Photon Emission Computed Tomography) on a triple flow bone scan give an any indication? The SPECT gives a 3D image with cross-sectional slices. This was discussed with the Nuclear Physicist at the scan centre who had been involved in the renal perfusion studies in kidney transplant patients at the Department of Urology, Post Graduate Institute of Medical Education and Research at Chandigarh, India.

Effort was made to develop a standardized procedure of reading the scan for consistency. It was decided that a SPECT analysis with a pixel count would be performed in the anterior and posterior scans defining a constant *REGION OF INTEREST* with a *CONTROL AREA*

for comparison.

The region of interest was defined on the head of femur and the pixel count used to ensure a constant area. The computer software of the Gamma camera scanner was used to evaluate the region. The control area was like-wise defined on the vertebra. The background ratio was used to eliminate any changes in the pixel count due to any variance in the quantity of isotope injected.

Since the pixel count could not be used as absolute values with reliability, a ratio of the pixel count of target area (H) to the control area (V) was used. Since these were taken from the same phase, they represented similar stages, although even the ratio was not expected to, or could have given a clear cut black and white picture of the outcome.

Consequently, in each patient and in each scan, pixel count in a well-defined region of interest with a pixel count in a

control area in L5 vertebra was recorded. Background to target ratio was taken into account while making the pixel counts.

Similar readings were recorded in all subsequent scans. The H/V (hip region of interest to the vertebral control area) ratio in the third phase of the skeletal image was compared. This ratio formed the basis of comparison in the pre-operative and all post-operative bone scans of each patient. In pre-operative scan, H1 was the sum of the pixel count in both the views-anterior and posterior. V1 was the sum of pixel count of both the vertebral control areas in the anterior and posterior readings. X1 was the ratio of H1/V1. Similarly, post-operatively the same ratios were taken, and designated as X2=H2/V2.

**OBSERVATIONS**

The study was conducted since 2007 in the Department of Orthopaedics, S. M. S. Medical College and Hospital, Jaipur, RJ, India, and subsequently by the author in his practice.

**Table 1: Age Distribution.**

Age Group	Number of cases	Percentage
16-20	13	24.24%
21-25	14	27.27%
26-30	10	18.18%
31-35	9	16.67%
36-40	7	13.64%
Total	53	100%

**Table 2: Sex Distribution.**

Sex	Number of cases	Percentage
Male	42	79%
Female	11	21%
Total	53	100%

**Table 3: Side Involved.**

Side of Disease	Number of cases	Percentage
Right	22	36.37%
Left	18	30.30%
Bilateral	13	33.33%
Total	53	100%

**Table 4: Etiological Cause of AVN Hip.**

Mode of Disease	Number of cases	Percentage
Alcohol Induced	16	30.30%
Steroid Induced	18	33.33%
Post-partum	3	6.07%
Idiopathic	16	30.30%
Total	53	100%

A total of 66 hips in 38 patients have been studied so far (Table 1 and 2). Table 3 shows the side involved. The etiology was steroid induced in 26%, post chronic alcoholism in 26%, post-partum in females in 7% and idiopathic in the remaining 41% (Table 4). Hip function was assessed by Harris' hip score (Table 5).

The AVN hip was graded according to the grading of and is shown in Table 6.

Pre-collapse (Ficat stage 1-2) hips were included in our study. Those patients with a Ficat Stage 3 or 4 hip who were poor and could not afford a joint replacement procedure were also

treated with a muscle pedicle graft procedure.

The radiological grading was done as per Marcus et al<sup>7</sup> (Table 7).

The bone scans were evaluated by performing the pixel counts in the anteroposterior (AP) and posteroanterior (PA) views in the region of interest (Femoral head 'H') and the control area (L5 vertebra 'V') both pre- and post- operatively as shown in Figures 1 and 2.

The ratio X2 (post-operative)/X1 (pre-operative) were

**Table 5: Preoperative Harris Hip Score.**

Harris Hip Score	Number of Hips	Percentage
Excellent	3	4.54%
Good	8	12.12%
Fair	12	18.18%
Poor	43	65.16%
Total	66	100%

**Table 6: Stage of AVN.<sup>1</sup>**

Stage of AVN	Number of Hips	Percentage
Stage 1	5	7.58%
Stage 2	31	46.96%
Stage 3	23	34.85%
Stage 4	7	10.61%
Total	66	100%

**Table 7: Radiological Stage.<sup>7</sup>**

Stage 1	9%
Stage 2	49%
Stage 3	33%
Stage 4	9%
Stage 5	0%
Stage 6	0%

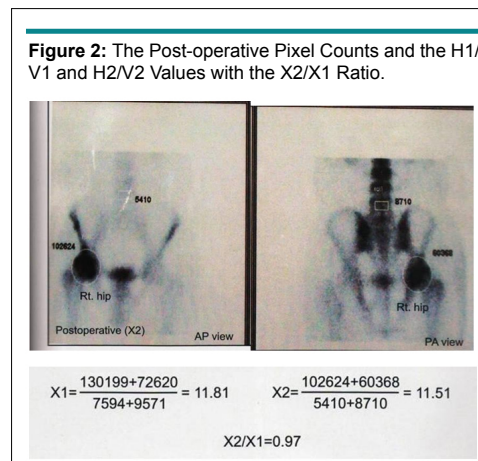
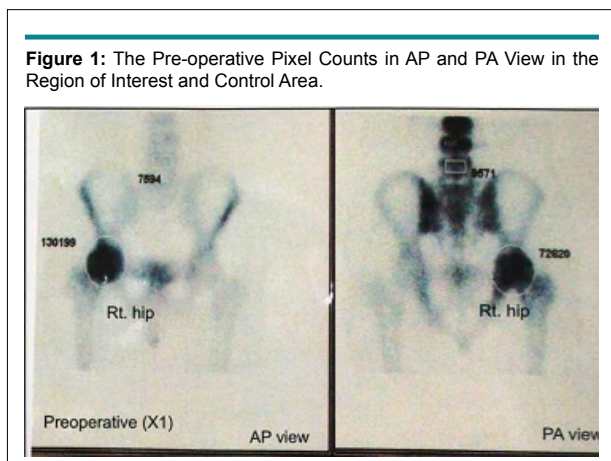


Table 8A: X2/X1 Ratio Distribution.		
X2/X1	Number of Hips	Percentage
0.9-1	8	12%
1.01-1.1	28	42%
1.11-1.2	17	26%
>1.2	13	20%

Table 8B: Statistical Analysis of X2/X1 Ratio.		
Statistical Group	X1	X2
Mean	9.10	10.62
Standard Deviation	4.23	4.91
SEM	.90	1.04
N	26	26

compared (Table 8A and 8B). The pre-operative ratio had a mean of 9.10 while the post-operative mean was 10.62 with a standard deviation of 4.23 and 4.91 respectively. The Paired *t*-test gave a *p*-value equal to 0.0104, considered statistically significant after six months' follow-up.

In 87% hips, a tensor fascia femoris graft was done in Grade 2 and Grade 3 AVN with anterior and superior involvement. Sartorius muscle pedicle was used in Grade 1 AVN (8%). In those hips with a posterior quadrant involvement, a quadratus femoris muscle pedicle graft was used through the posterior approach (5%). Figure 3 and 4 shows the X2/X1 ratio after six months of surgery.

The pre- and post-operative scans were compared as the ratio X2/X1. The ratio distribution and statistical analysis of the results is shown in Table 8A and 8B.

The results indicated some surprising values but useful inferences could be drawn. Although it was difficult to comment

on revascularization with any degree of certainty, the ratios did reveal a predictive value in the outcome.

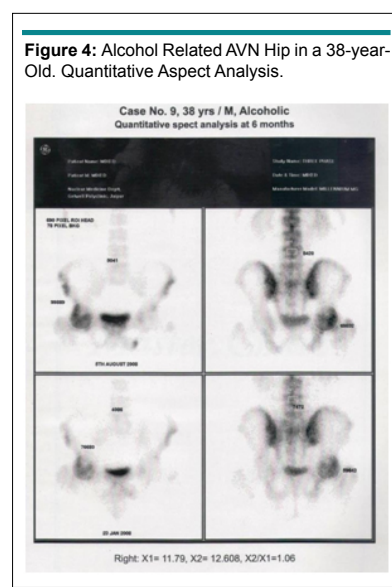
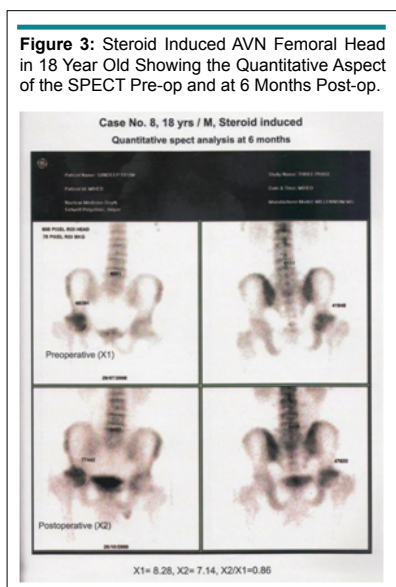
The ratio decreased, remained static or marginally increased in those patients where the disease was contained, even reversed to some extent.

The ratio continues to be altered for a period of 2 years.

It significantly increased in those patients where the disease progressed, and eventually led to osteoarthritic changes or the patient was forced to undergo athroplasty. It continued to rise in these patients for a period of up to 2 years after which it became static.

This was inferred on the changes in the Harris hip score clinically (Table 9).

The Harris hip score showed an improvement in 65% cases, remained unchanged in 15% cases, and showed deteriora-



**Table 9:** Statistical Analysis of the Pre- and Post-Op Harris Hip Score.

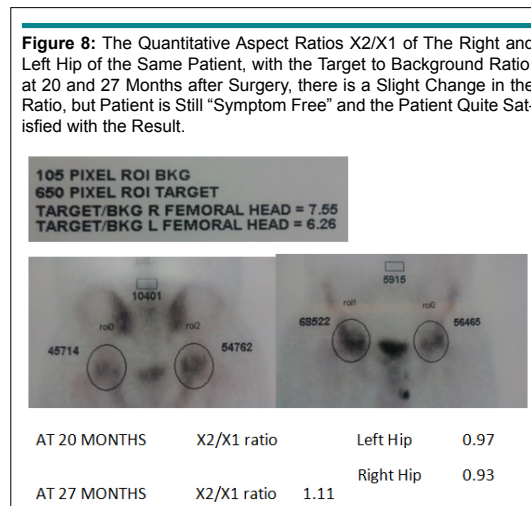
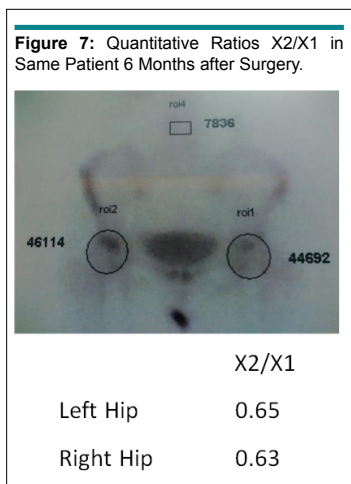
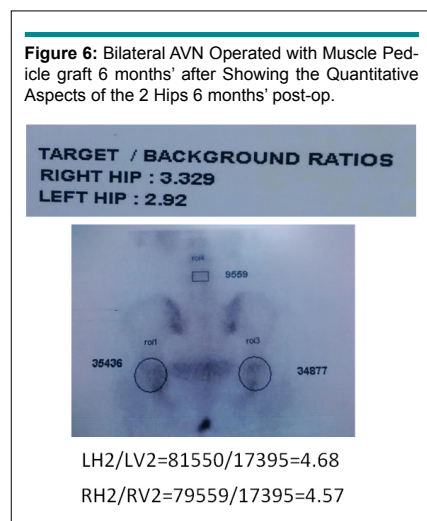
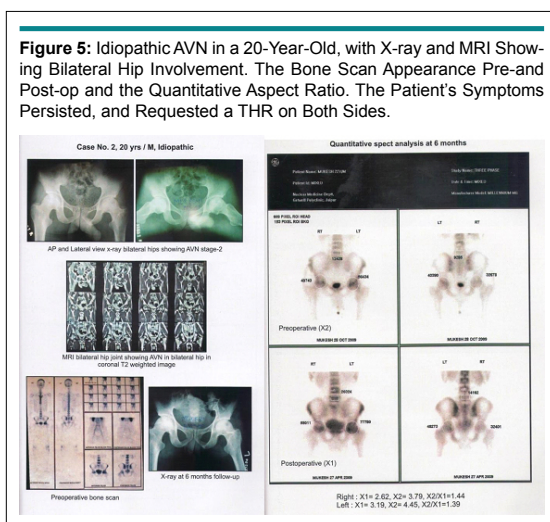
Statistical Group	Pre-Op Harris Hip Score	Post-Op Harris Hip Score
Mean	59.08	66.50
Standard Deviation	10.44	9.94
SEM	2.05	1.95
N	26	26

tion in 20% cases, with a *p*-value of 0.0001 which was statistically significant. Only four out of 66 opted for total hip replacement (THR).

When the radiological status was evaluated post-operatively using the Marcus et al<sup>7</sup> grading as used pre-operatively, it showed that there was a change in the radiological status after six to twelve months. Thirty two percent hips improved by one stage. Marcus et al<sup>7</sup> stage 3 hips improved to stage 2, stage 2

to stage 1 and stage 1 to no radiological evidence. Forty three percent hips remained unchanged radiologically. Twenty five percent deteriorated in radiological stage. Six percent required or desired joint replacement.

Figure 5 shows the X-ray, MRI and pre-operative bone scan together, with the post-operative SPECT and the pixel counts and the X2/X1 ratio.



**Table 10:** Prognostic Significance of X1/X2 Ratio.

Significance	Ratio	Percentage of Hips
Disease arrested and reversed	0.9 to 1.0	12%
Disease arrested and static	>1.0 to 1.1	42%
Disease progressed but no arthritic evidence	>1.1 to 1.2	26%
Disease progressed to arthritis	>1.2	20%

In the SPECT analysis in subsequent cases (Figure 6), a target background ratio was also fixed.

A serial change in the SPECT analysis in a patient with bilateral idiopathic AVN over a period of 6 months, 20 months and 27 months is shown in Figures 6, 7 and 8.

We could draw the following inferences:

- The ratio decreases as the revascularization occurs or disease is contained.
- It continues to alter over a period of 2 years.
- No further rise occurs after 2 years becomes static.

The prognostic significance as gauged by us from the study data is shown in Table 10.

We feel it can be reliably used as a predictor variable with prognostic value.

The post-operative complications were restriction of movement due to presence of the graft, meralgia paraesthetica due to the surgical approach used and low back pain and shortening of >1 cm, which could possibly be a consequence of the disease itself. No patient suffered a fracture of the neck of femur or infection.

**CONCLUSION**

It would appear that *THE IDEAL CANDIDATE* for a muscle pedicle graft is a young patient, with no or minimal degeneration of the acetabular cartilage or a crescent sign or collapse of the femoral head. It could also benefit the young patients, without femoral head collapse but with extensive osteonecrotic involvement of the femoral head (a combined necrotic angle of >2000 or femoral head involvement of >50%). Tc-99 bone scan with SPECT analysis could be used as a monitor for the progression of the disease, and could provide a useful indicator of prognostic value as to which patient may eventually require arthroplasty.

**ACKNOWLEDGEMENT**

The author gratefully acknowledges the help rendered by Dr. Karun Sethi, Nuclear Physicist, Gamma Imaging and Nuclear Medicine section, Get-well Diagnostic Centre, Opposite Jay kay

Lon Hospital, Jaipur, in the SPECT analysis of the bone scans, and maintaining their records.

**REFERENCES**

1. Ficat RP, Arlet J. *Ischaemia and necrosis of bone*, Baltimore etc. Williams and Wilkin. 1980; 171-182.
2. Canale ST, Beaty JH. Management of osteonecrosis of head of femur. *Campbell's Operative Orthopaedics*. 11<sup>th</sup> ed. Philadelphia, USA: Elsevier; 2007.
3. Bakshi DP. Treatment of AVN of the femoral head by drilling and muscle pedicle bone grafting. *J Bone Joint Surg Br*. 1991; 73(2): 241-245. Web site. <http://www.bjj.boneandjoint.org.uk/content/73-B/2/241.short>. Accessed November 13, 2016.
4. Collier BD, Carrera GF, Johnson RP, et al. Detection of femoral head avascular necrosis in Adults by SPECT. *J Nucl Med*. 198; 26(9): 979-987. Web site. <http://europepmc.org/abstract/med/3875700>. Accessed November 13, 2016.
5. Hull A, Hattner RS, Vincente S. Prospective Scintigraphic evaluation of avascular necrosis (AVN) of the femoral head in renal transplant recipients. *J Nucl Med*. 1979; 20(1): 646-650. doi: [10.1016/S0009-9260\(85\)80012-X](https://doi.org/10.1016/S0009-9260(85)80012-X)
6. Droll KP, Prasad V, Ciorau A, Gray BG, McKee MD. The use of postoperative bone scintigraphy to predict graft retention. *Can J Surg*. 2007; 50(4): 261-265. Web site. <http://search.proquest.com/openview/c72d1a9bfbb03055958cdb4eae994bc5/1?pq-origsite=gscholar&cbl=41665>. Accessed November 13, 2016.
7. Marcus ND, Enneking WF, Massam RA. The silent hip in idiopathic aseptic necrosis: Treatment by bone grafting. *J Bone Joint Surg Am*. 1973; 55(7): 1351-1366. Web site. <http://jbjs.org/content/55/7/1351>. Accessed November 13, 2016.