

## Case Report

# Palliative Embolization in Recurrent Nodal Bleeding in Nasopharyngeal Cancer: Case Report and Review of Literature

Mohammed A. Naseer, MD<sup>1\*</sup>; Sharif A. W. Al Aryadh, MD, FRCR<sup>2</sup>; Ravi M. Pedapenki, MD, DM<sup>1</sup>

<sup>1</sup>Department of Oncology, Salmaniya Medical Complex (SMC), Bahrain

<sup>2</sup>Department of Radiology, Salmaniya Medical Complex (SMC), Bahrain

\*Corresponding author

Mohammed A. Naseer, MD

Department of Oncology, Salmaniya Medical Complex (SMC), Bahrain; E-mail: [drnaseermohd@gmail.com](mailto:drnaseermohd@gmail.com)

### Article information

Received: July 28<sup>th</sup>, 2020; Revised: September 12<sup>th</sup>, 2020; Accepted: September 30<sup>th</sup>, 2020; Published: October 7<sup>th</sup>, 2020

### Cite this article

Naseer MA, Al Aryadh SAW, Pedapenki RM. Palliative embolization in recurrent nodal bleeding in nasopharyngeal cancer: Case report and review of literature. *Palliat Med Hosp Care Open J.* 2020; 6(2): 16-18. doi: [10.17140/PMHCOJ-6-138](https://doi.org/10.17140/PMHCOJ-6-138)

### ABSTRACT

Arterial embolization is used as one of the palliative procedure in the control of bleeding. We have demonstrated this procedure to be effective in the control of the bleeding in various malignancies in our center. This is our first case report in a teenaged nasopharyngeal cancer patient who had exhausted all his treatment as he had progressive disease and recurrent bleeding episodes from the recurrent neck nodal mass. This was controlled well with arterial embolization with no significant side effects.

### Keywords

Nasopharyngeal cancer; Recurrent nodal bleeding; Embolization.

### OVERVIEW

Embolization is used since 1970 after Duggan introduced this procedure.<sup>1</sup> It has been used in the treatment of spontaneous and traumatic epistaxis, as a pre-operative procedure to control operative bleeding in the vascularized tumors; vascular defects and juvenile nasopharyngeal angiofibromas as well as palliative bleeding in the head and neck tumors.<sup>1</sup> The embolization involves an embolic agent to be introduced into the lumen of blood vessel supplying the tumor causing its closure which subsequently minimize and stops the bleeding.<sup>1,2</sup>

Our patient in discussion is a teenaged Bahraini boy who was diagnosed with loco-regionally advanced nasopharyngeal cancer at the age of 15-years. During the course of his treatment he received all standard treatment options including chemotherapy in neo-adjuvant, concurrent, adjuvant and palliative forms, radiotherapy, surgery, and immunotherapy. He had disease progression and occlusion of bilateral jugular venous flow due to tumorous mass compression. He had recurrent neck nodal mass bleeding which was finally controlled after external carotid artery embolization with the help of our dedicated interventional radiologist.

### CASE REPORT

Mr. SH was 15-years-old Bahraini boy in October 2017, at the time

of diagnosis of loco-regionally advanced nasopharyngeal carcinoma clinically staged T2N3M0. Excisional biopsy of the lymph nodal mass as well as biopsy from the nasopharyngeal mass showed features of non-keratinizing carcinoma. He was treated with 3 cycles of neo-adjuvant chemotherapy followed by concurrent chemo-radiotherapy in Turkey between January 29, 2018 to March 16, 2018. He received weekly Cisplatin chemotherapy during intensity-modulated radiotherapy (IMRT) technique of radiation treatment and received a total dose of 66 Gy in 33 fractions.

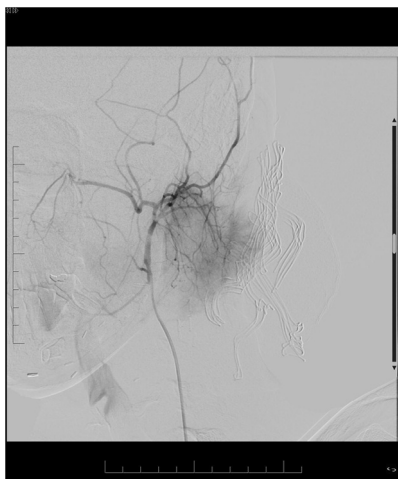
Post-treatment positron emission tomography and computed tomography (PET-CT) scan (June 11, 2018) showed almost complete regression of nasopharyngeal mass with complete resolution of bilateral para-pharyngeal nodes with residual left upper cervical lymph nodes. He had presented to ENT department of Salmaniya Medical Complex hospital in December 2018 with history of nasal bleeding. Fibro-optic endoscopic examination showed blood crust in the nose with no mass seen in the nasopharyngeal area. Magnetic resonance imaging (MRI) reviewed revealed left level II & level III lymph node metastasis. Ultrasound-guided (USG) guided biopsy from the left cervical nodal mass was positive for recurrent metastatic non keratinizing carcinoma. He was discussed in the multidisciplinary team (MDT) meeting and boarded abroad to Turkey where he had left neck dissection on January 04,

2019 followed by 3 cycles of adjuvant chemotherapy with Taxol plus carboplatin regimen. A PET-CT scan on October 18, 2019 in Turkey showed disease progression, so he received 5 cycles of palliative chemotherapy using BEP regimen. Restaging work up in Turkey by PET-CT scan on January 03, 2020 and MRI on January 04, 2020 showed further disease progression. He was discussed in the combined MDT meeting in favor of stereotactic body radiotherapy (SBRT) with the risk of carotid blowout as possible complication for which the family did not agree. Therefore, he was treated with metronomic chemotherapy using low dose methotrexate along with narcotic analgesia.

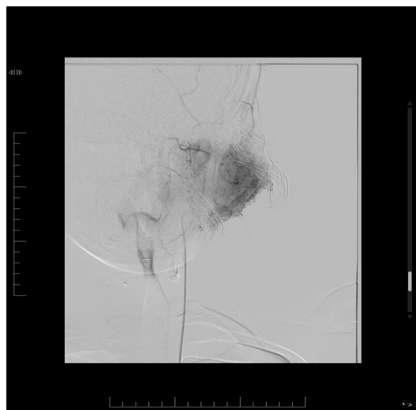
He was seen in the Oncology Department of Salmaniya Medical Complex for the first time after his treatment in Turkey in January 2020. He was advised programmed death-ligand 1 (PDL1) testing on his original biopsy specimen which was positive with 95% expression. He was thoroughly discussed along with his father regarding further treatment using immunotherapy (Pembrolizuma-

b 3 mg/Kg) along with chemotherapy (Cisplatin 75 mg/m<sup>2</sup>) every 21-days. Accordingly, he had received 4 cycles, last cycle on May 26, 2020. Post-treatment MRI (June 14, 2020) showed features of further disease progression in the form of two large enhancing conglomerated masses in the left para pharyngeal and lower cervical region. It was extending to subcutaneous skin with involvement of carotid, parotid spaces and para spinal structures with features suggestive of perineural spread. He also had bilateral cervical adenopathy with focal area of loss of signal in the left jugular vein suspicious of tumorous infiltration/thrombosis. He was admitted to Salmaniya Medical Complex on June, 17, 2020 for further evaluation. Doppler USG neck done on June 22, 2020 showed absence of flow within the internal jugular veins bilaterally due to mass effect however normal flow noted in both common carotid arteries. In view of further disease progression, it was decided to stop the chemo-immunotherapy. He had neck pain which required narcotic analgesia. He was started on therapeutic anticoagulant injection enoxaparin 80 mg on June 23, 2020 following which he started to have profuse bleeding from the left neck nodal mass which was temporarily stopped after tight neck pressure dressing and injection protamine sulphate. Subsequently he received 3 units Fresh Frozen Plasma and one-unit Packed Red Blood Cells as Hemoglobin dropped from 10.2 to 8.8. Further anti-coagulant treatment stopped. He used to have minimal oozing with another episode of profuse bleeding on June 29, 2020. Again had tight pressure dressing with one unit of PRBC transfusion. A consultation was arranged with our interventional radiologist for tumor transarterial embolization and done on June 30, 2020 with 300-500-micron Polyvinyl alcohol particles through femoral artery approach. Left external carotid artery catheterization done with superselective catheterization with microcatheter (Figures 1 and 2). Post embolization image (Figure 3) showed reduction in hyperemia with no immediate complications.

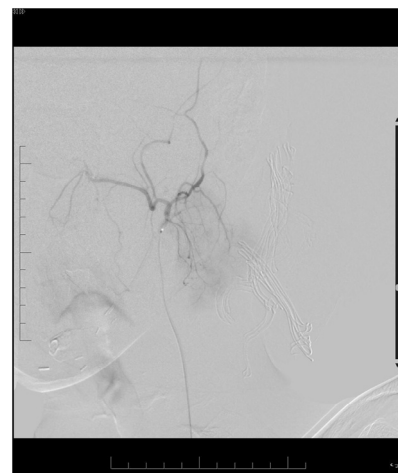**Figure 1.** Slightly Delayed Image Showing Peripheral Filling of Arterioles and Capillaries Along the Ulceration surface



**Figure 2.** Selective Catheterization of the External Carotid Artery Showing Marked Hyperemia in the Area of Parotid Gland and Neck



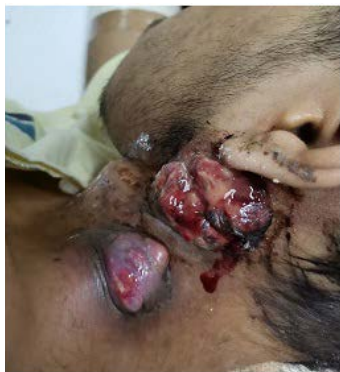**Figure 3.** Post-EMBOLIZATION with PVA Particles Showing Reduction of Hyperemia and Embolization of Small Arteriole and Capillaries



Post-embolization he had neck pain which was exacerbated and required intravenous paracetamol and morphine analgesia. He was discharged from the hospital after 5-days with change

of neck dressing with minimal oozing (Figure 4). He was prescribed with oral morphine which was changed to Codeine plus paracetamol combination as he felt dizzy with morphine. Oral antibiotics continued for one week. Patient is still alive with no further episode of bleeding (2.5-months).

Figure 4. Photograph of Patient Post-Embolization on Day 5



## DISCUSSION

Loco-regional recurrence is the primary cause of failure in the head and neck cancer after completing the planned treatment which consists of concurrent chemo-radiotherapy followed by neck dissection if there is residual neck disease. Dangerous hemorrhages requiring packed red blood cell transfusion is noted in some recurrent head and neck cancer due to infiltration of blood vessels.<sup>1</sup> Therefore, diagnostic angiography with simultaneous embolization of the bleeding vessel is an effective therapeutic and palliative option as other palliative procedures are limited or even impossible. Embolization is a minimally invasive procedure done under local anesthesia through the femoral artery using Seldinger technique. The indications for embolization have been broadened with new embolization agents ranging such as coils, liquid embolic agent, particles, and drug eluting beads have been used.<sup>3</sup> Other options are drug eluting beads (DEB)—trans arterial chemoembolization (TACE) with chemotherapeutic agent loaded on microbeds for cancer treatment and palliative management.<sup>3</sup> Contrast medium (Omnipaque) is administered under X-ray fluoroscopy through a catheter introduced to localized the source of bleeding with permanent closure of bleeding vessels using appropriate embolic agent.<sup>1</sup> According to a study done by Rzewnicki et al<sup>1</sup> post-procedure complication was noted in the form of recurrent bleeding (5%) which required surgical ligation of external carotid artery, head-

ache (18.4%) lasting up to 3-days and facial edema in 7.8%. Other complications reported in the literature include ischemic stroke, cranial nerve paresis or blindness.<sup>1,4</sup> Tumor embolization has long lasting control of bleeding due to occlusion of microcirculation and was noted to be effective in 86% of their study population.<sup>1</sup> In long-term follow-up embolization has prolonged the life of these patients with recurrent tumors.<sup>5</sup>

## CONCLUSION

Endovascular embolization is an effective and safe procedure by well-trained interventional radiologist in the management of acute hemorrhage from advanced head and neck tumors.

## CONSENT

Verbal consent from the patient's father has been obtained.

## CONFLICTS OF INTEREST

The authors declare that they have no conflicts of interest.

## REFERENCES

1. Rzewnicki I, Kordecki K, Janica ALJ, Pulawska-Stalmach M, Kordecki JK, et al. Palliative embolization of hemorrhages in extensive head and neck tumors. *Pol J Radiol.* 2012;77(4): 17-21. doi: 10.12659/pjr.883624
2. GemmeteJJ, Ansari SA, McHugh J, Gandhi D. Embolization of vascular tumors of the head and neck. *Neuroimaging Clin N Am.* 2009; 19(2): 181-198. doi: 10.1016/j.nic.2009.01.008
3. Alaraj A, Pytynia K, Carlson AP, Krishna PH, Charbel FT, Amin-Hanjani S, et al. Combined preoperative onyx embolization and protective internal carotid covered stent placement for treatment of glomus jugular tumor: Review of literature and illustrative case. *Neurol Res.* 2012; 34(6): 523-529. doi: 10.1179/1743132812Y.0000000036
4. Lazzaro MA, Badruddin A, Zaidat O, Darkhabani Z. Endovascular embolization of head and neck tumors. *Frontiers in Neurology.* 2011; 2: 1-9. doi: 10.3389/fneur.2011.00064
5. Storck K, Kreiser K, Hauber J, Buchberger A-M, Staudenmaier R, Kreutzer K, et al. Management and prevention of acute bleeding in the head and neck area with interventional radiology. *Head Face Med.* 2016; 12: 6. doi: 10.1186/s13005-016-0103-3