

Mini Review

*Corresponding author

Solwayo Ngwenya, MBChB, DFRSH, MRCOG
Consultant Obstetrician and
Gynaecologist
Head of Department of Obstetrics and
Gynaecology;
Clinical Director
Mpilo Central Hospital, Vera Road
Mzilikazi Founder and Chief Executive
Officer, Royal Women's Clinic
52A Cecil Avenue, Hillside
Bulawayo, Matabeleland, Zimbabwe
E-mail: drsolvingwe@yahoo.co.uk

Volume 4 : Issue 1

Article Ref. #: 1000PRRMOJ4131

Article History

Received: August 30th, 2016

Accepted: September 16th, 2016

Published: September 19th, 2016

Citation

Ngwenya S. Pneumocystis carinii pneumonia; lost lives in pregnancy: Chemoprophylaxis saves lives. *Pulm Res Respir Med Open J*. 2016; 4(1): 5-8. doi: [10.17140/PRRMOJ-4-131](https://doi.org/10.17140/PRRMOJ-4-131)

Copyright

©2016 Ngwenya S. This is an open access article distributed under the Creative Commons Attribution 4.0 International License (CC BY 4.0), which permits unrestricted use, distribution, and reproduction in any medium, provided the original work is properly cited.

Pneumocystis Carinii Pneumonia; Lost Lives in Pregnancy: Chemoprophylaxis Saves Lives

Solwayo Ngwenya, MBChB, DFRSH, MRCOG*

Consultant Obstetrician and Gynaecologist, Head of Department of Obstetrics and Gynaecology, Mpilo Central Hospital, Vera Road, Mzilikazi Founder and Chief Executive Officer, Royal Women's Clinic, 52A Cecil Avenue, Hillside, Bulawayo, Matabeleland, Zimbabwe

ABSTRACT

The advent of HIV/AIDS brought opportunistic infections such as *Pneumocystis jirovecii* pneumonia (PJP), formerly known as *Pneumocystis carinii* pneumonia (PCP) to the fore. This is a fungal opportunistic infection that is an human immunodeficiency virus infection and acquired immune deficiency syndrome (HIV/AIDS) defining illness. It poses significant risks to both the mother and the fetus. Pneumocystis carinii pneumonia can have a sub-clinical insidious onset but can rapidly progress to acute respiratory failure leading to maternal and fetal demise. The best form of management of pneumocystis carinii pneumonia is prevention. Widespread chemoprophylaxis with co-trimoxazole reduces morbidity and mortality. The management calls for a multidisciplinary approach involving the physician, obstetrician and pneumologist. Pneumocystis carinii pneumonia has a more aggressive course during pregnancy with increased morbidity and mortality, maternal and fetal outcomes remaining dismal. Therefore, it is important that widespread HIV testing and use of co-trimoxazole chemoprophylaxis are made readily available to reduce morbidity and mortality. It must be a differential diagnosis of one pregnant HIV seropositive patient presenting with pulmonary symptomatology.

KEYWORDS: Pneumocystis carinii pneumonia; Pregnancy; HIV/AIDS; Maternal mortality; Co-trimoxazole; Outcomes.

INTRODUCTION

Pneumocystis carinii pneumonia is spread by the airborne route. It caused significant morbidity and mortality in the early stages of the HIV/AIDS pandemic before the advent of anti-retroviral chemotherapeutic agents. It is now decreasing in incidence due to anti-pneumocystis¹ therapy but still causes maternal deaths in HIV infected pregnant mothers. Historically, pneumonia during pregnancy has been associated with increased morbidity and mortality compared to non-pregnant women.² Acute lung injury during pregnancy results in high morbidity and mortality for both the mother and the fetus.³ In the USA, *Pneumocystis carinii* pneumonia is the most common cause of AIDS-related death in pregnant women.⁴ Many HIV-infected persons in the USA remain at high risk of opportunistic infection because they are unaware of their HIV infection.⁵

It therefore remains a subject of great importance to the population especially in areas with high prevalence of HIV/AIDS. There is a proven chemoprevention agent that is safe and reduces morbidity and mortality in HIV/AIDS patients. All efforts must be made to save lives of pregnant women regardless of their HIV serostatus.

PATHOGENESIS

The causative infective agent is the unicellular *Pneumocystis jirovecii*. This is a common fungus

found in the environment and rarely causes disease in healthy people. However in immune-compromised patients, like HIV/AIDS and cancer patients it causes pneumonia. The fungus can colonise the oropharynx, trachea, trachea-bronchial, bronchial, alveoli and lung parenchyma areas. The microorganism can spread throughout the lungs.

Most pneumocystosis pathophysiological changes result from the parasite's attachment and proliferation in the lungs, resulting in a filling of alveoli with masses of the microorganism.⁶ A host response takes place by hypertrophy and hyperplasia involving type 2 epithelial alveolar cells. The effect of this is interference in pulmonary gaseous exchange leading to respiratory compromise and failure.

CLINICAL PRESENTATION

Pneumocystis carinii pneumonia can have a sub-clinical insidious onset but can rapidly progress to acute respiratory failure⁷ leading to the death of the mother⁸ and the fetus. Patients may present with cough, chest pains and worsening shortness of breath.⁹ Clinically, they may be tachypnoic, tachycardic, cyanosed and respiratory distress. It must be considered as a differential diagnosis in all HIV seropositive patients complaining of chest problems.

The investigations such as arterial blood gases reveal profound hypoxia in *Pneumocystis carinii pneumonia* patients. The chest-x-ray is typically described as showing a diffuse interstitial pneumonia (Figure 1). The chest-x-ray may also reveal pneumothoraces or pleural effusions. Ultrasonographic appearances include consolidation with dynamic air bronchograms and pleural effusions.¹⁰

Definitive diagnosis is with molecular tests such as polymerase chain reaction (PCR). Obtaining specimens for such testing may be difficult.¹¹ The diagnosis is confirmed by the detection of trophozoites and/or cysts of *Pneumocystis jirovecii*

in bronchoalveolar lavage samples by using several staining techniques.¹ The use of PCR with the standard immunofluorescent or colorimetric tests allows rapid and accurate diagnosis. This greatly improves the commencement of chemotherapeutic agents and may improve outcomes. Bronchoalveolar lavage samples can be obtained by rigid or flexible bronchoscopy. Besides bronchoalveolar lavage samples other samples that can be tested include oropharyngeal wash, sputum and blood.¹¹

MANAGEMENT

The best form of management of pneumocystis carinii pneumonia is prevention. Widespread chemoprophylaxis with a daily dose of co-trimoxazole (trimethoprim-sulfamethoxazole) is now recommended by the World Health Organization (WHO) for all HIV seropositive patients.^{12,13} A systematic review of the literature has concluded that it is safe to give in pregnant and breastfeeding HIV seropositive patients.¹⁴ The fetal adverse effects are outweighed by the benefits hence co-trimoxazole is given in pregnancy.

The management calls for a multidisciplinary approach involving the physician, obstetrician and pneumologist. Pregnant patients presenting in acute state present a difficult dilemma to the clinician. There could be a high possibility of immediate maternal and fetal poor outcomes. The treatment involves oxygen therapy and high doses of co-trimoxazole. The other drug that can be used is pentamidine in combination with co-trimoxazole. Pentamidine can be given in an aerosolized form.¹⁵

Those patients presenting with pneumothoraces with respiratory distress will need urgent tube thoracostomy to relieve the pneumothoraces and respiratory distress. Patients may need to be admitted to the intensive care unit (ICU) for ventilatory support. Difficult decisions about delivery may have to be taken, at times compromising fetal health if the fetus is premature. Delivery may improve ventilation and improve maternal outcomes. Those collapsing patients with live fetuses should

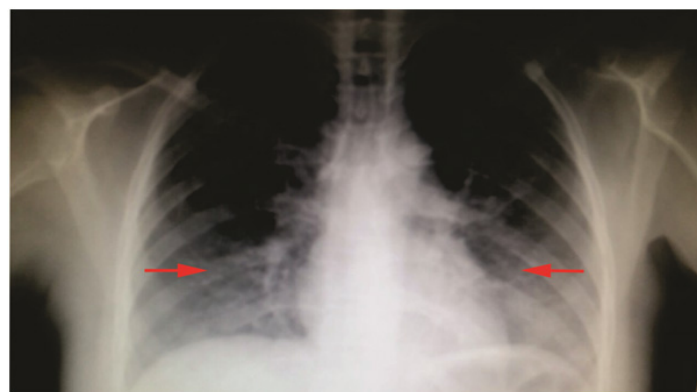


Figure 1: A chest X-ray showing bilateral interstitial pneumonia typical of *Pneumocystis carinii pneumonia*.

have peripartum caesarean sections to salvage the fetuses. Fetal complications include iatrogenic prematurity,¹⁶ stillbirths and congenital transplacental infection.¹⁷⁻¹⁹

Pneumocystis carinii pneumonia has a more aggressive course during pregnancy with increased morbidity and mortality, maternal¹⁶ and fetal outcomes remaining dismal.⁴

CONCLUSION

Pneumocystis carinii pneumonia is a serious infection that causes significant maternal and fetal morbidity and mortality in HIV/AIDS patients. Widespread HIV testing and use of Co-trimoxazole chemoprophylaxis can reduce maternal and fetal morbidity and mortality. Co-trimoxazole is safe in pregnancy and breastfeeding. It must be a differential diagnosis of any pregnant HIV seropositive patient presenting with pulmonary symptomatology.

AUTHOR'S CONTRIBUTION

This is the sole work of Mr. S. Ngwenya.

REFERENCES

1. EL Fane M, Sodqi M, Oulad Lahsen A, et al. Pneumocystosis during HIV infection. *Rev Pneumol Clin*. 2016; 72(4): 248-254. doi: [10.1016/j.pneumo.2016.04.004](https://doi.org/10.1016/j.pneumo.2016.04.004)
2. Goodnight WH, Soper DE. Pneumonia in pregnancy. *Crit Care Med*. 2005; 33(10 Suppl): S390-S397. doi: [10.1097/01.CCM.0000182483.24836.66](https://doi.org/10.1097/01.CCM.0000182483.24836.66)
3. Tamaki Y, Higa F, Tasato D, et al. Pneumocystis jirovecii pneumonia and alveolar haemorrhage in a pregnant woman with human T cell lymphotropic virus type-1 infection. *Intern Med*. 2011; 50(4): 351-354. doi: [10.2169/internalmedicine.50.4482](https://doi.org/10.2169/internalmedicine.50.4482)
4. Ahmad H, Mehta NJ, Manikal VM, et al. Pneumocystis carinii pneumonia in pregnancy. *Chest*. 2001; 120(2): 666-671. doi: [10.1378/chest.120.2.666](https://doi.org/10.1378/chest.120.2.666)
5. Fitzpatrick M, Brooks JT, Kaplan JE. Epidemiology of HIV-Associated Lung Disease in the United States. *Semin Respir Crit Care Med*. 2016; 37(2): 181-198. doi: [10.1055/s-0036-1572556](https://doi.org/10.1055/s-0036-1572556)
6. Cailliez JC, , Séguy N, Denis CM, et al. Pneumocystis carinii: An atypical fungal micro-organism. *J Med Vet Mycol*. 1996; 34(4): 227-239. Web site. <http://www.tandfonline.com/doi/abs/10.1080/02681219680000401?journalCode=immy19>. Accessed August 29, 2016
7. Albino JA, Shapiro JM. Respiratory failure in pregnancy due to Pneumocystis carinii: Report of a successful outcome. *Obstet Gynecol*. 1994; 83(5 Pt 2): 823-824. Web site. <http://europepmc.org/abstract/med/8159362>. Accessed August 29, 2016
8. Minkoff H, deRegt RH, Landesman S, Schwarz R. Pneumocystis carinii pneumonia associated with acquired immunodeficiency syndrome in pregnancy: A report of three maternal deaths. *Obstet Gynecol*. 1986; 67(2): 284-287. Web site. http://journals.lww.com/greenjournal/abstract/1986/02000/pneumocystis_carinii_pneumonia_associated_with.24.aspx. Accessed August 29, 2016
9. Curtis M, Patel A, Degeyter K, Neitzschman H. Radiology of the month: Spontaneous Bilateral pneumothoraces in an hiv-infected patient. *J La State Med Soc*. 2016; 168(3): 120-121.
10. Galstian GM, Novikov VA, Troitskaia VV, et al. Lung ultrasonography for the diagnosis of pneumonia in pregnant women with blood system tumors. *Ter Arkh*. 2015; 87(1): 79-87. Web site. <http://europepmc.org/abstract/med/25823274>. Accessed August 29, 2016
11. van Halsema C, Johnson L, Baxter J, et al. Short communication: Diagnosis of pneumocystis jirovecii pneumonia by detection of DNA in blood and oropharyngeal wash, compared with sputum. *AIDS Res Hum Retroviruses*. 2016; 32(5): 463-466. doi: [10.1089/AID.2015.0213](https://doi.org/10.1089/AID.2015.0213)
12. Church JA, Fitzgerald F, Walker AS, Gibb DM, Prendergast AJ. The expanding role of co-trimoxazole in developing countries. *Lancet Infect Dis*. 2015; 15(3): 327-339. doi: [10.1016/S1473-3099\(14\)71011-4](https://doi.org/10.1016/S1473-3099(14)71011-4)
13. Connelly RT, Lourwood DL. Pneumocystis carinii pneumonia prophylaxis during pregnancy. *Pharmacotherapy*. 1994; 14(4): 424-429. doi: [10.1002/j.1875-9114.1994.tb02832.x](https://doi.org/10.1002/j.1875-9114.1994.tb02832.x)
14. Forna F, McConnell M, Kitabire FN, et al. Systematic review of the safety of trimethoprim-sulfamethoxazole for prophylaxis in HIV-infected pregnant women: Implications for resource-limited settings. *AIDS Rev*. 2006; 8(1): 24-36.
15. Sarti GM. Aerosolized pentamidine in HIV. Promising new treatment for Pneumocystis carinii pneumonia. *Postgrad Med*. 1989; 86(2): 54-69. doi: [10.1080/00325481.1989.11704352](https://doi.org/10.1080/00325481.1989.11704352)
16. Gates HS Jr, Barker CD. Pneumocystis carinii pneumonia in pregnancy: A case report. *J Reprod Med*. 1993; 38(6): 483-486. Web site. <http://europepmc.org/abstract/med/8331631>. Accessed August 29, 2016
17. Kurennaia SS, Shlopov VG, Mirovich Dlu, Demina TN, Berko AT. Pneumocystosis in a pregnant patient complicated by transplacental infection and intrauterine fetal death. *Akush Ginekol*. 1985; (4): 72-73. Web site. <http://europepmc.org/abstract/med/3159302>. Accessed August 29, 2016
18. Pavlica F. The first observation of congenital pneumocystic pneumonia in a fully developed stillborn child. *Ann Paediatr*.

1962; 198: 177-184. Web site. <http://europepmc.org/abstract/med/14484595>. Accessed August 29, 2016

19. Mortier E, Pouchot J, Bossi P, Molinie V. Maternal-fetal transmission of *Pneumocystis carinii* in human immunodeficiency virus infection. *N Engl J Med*. 1995; 332(12): 825. doi: [10.1056/NEJM199503233321219](https://doi.org/10.1056/NEJM199503233321219)