

Review

Corresponding author

Sean L. Kitson, PhD

Department of Biocatalysis and Isotope Chemistry, Almac, 20 Seagoe Industrial Estate, Craigavon, BT63 5QD, UK

E-mail: sean.kitson@almacgroup.com

Volume 1 : Issue 1

Article Ref. #: 1000NOJ1102

Article History

Received: March 17th, 2014

Accepted: March 31st, 2014

Published: April 11th, 2014

Citation

Kitson SL. Positron Emission Tomography Neuro-Imaging. *Neuro Open J.* 2014; 1(1): 7-10. doi: [10.17140/NOJ-1-102](https://doi.org/10.17140/NOJ-1-102)

Positron Emission Tomography Neuro-Imaging

Sean L. Kitson*

Department of Biocatalysis and Isotope Chemistry, Almac, 20 Seagoe Industrial Estate, Craigavon, BT63 5QD, UK

ABSTRACT

Positron Emission Tomography (PET) is a powerful imaging technique exploring *in vivo* brain functions. Today PET is becoming an essential tool in specialist clinical neurology settings particularly for diagnosing Alzheimer's, Parkinson's and epilepsy disease states. This inaugural article aims to deliver a brief insight into PET techniques in the diagnosis of neurological diseases including multiple sclerosis.

KEYWORDS: Radiotracer; Positron Emission Tomography (PET); Neurology; Alzheimer's disease; Parkinson's disease; Epilepsy; Multiple sclerosis.

INTRODUCTION

The imaging of the human body can be traced back to 1895 with the discovery of x-rays by the 1901 Nobel Laureate Wilhelm Conrad Röntgen.¹ Currently a variety of imaging techniques are used to effectively assist the diagnosis of disease in humans. These include Computed Tomography (CT), Magnetic Resonance Imaging (MRI) and Single Photon Emission Computed Tomography (SPECT) all capable of generating 3-D anatomical images of the human body.² Since the 1990s a revolutionized imaging tool for Nuclear Medicine has emerged called Positron Emission Tomography (PET).³

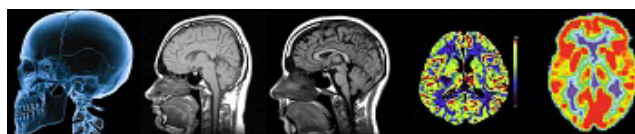


Figure 1: From Left to Right: examples of brain images produced by X-ray, CT, MRI, SPECT and PET techniques.

PET, in contrast to other conventional imaging techniques, provides an insight into the biochemical/physiological processes of the human body.⁴ The biochemistry of the body is altered when it is in a disease state. For example, PET imaging has the capability to detect certain cancer stages before apparent structural changes appear, whereas MRI is unable to see these subtle changes. PET utilizes 'positron' emitting radiotracers to deliver images of the human body.

These radiotracers must be synthesized very quickly due to the short half-life of the nuclide ($t_{1/2} < 20$ mins for carbon-11; $t_{1/2} < 110$ mins for fluorine-18).⁵

Non-invasive PET imaging has been used as a research tool since the 1970s. By the 1990s this advance in technology aided the diagnosis, staging and monitoring of disease states in patients.⁶ In 1953, the pioneering work of Brownell and Sweet at Massachusetts General Hospital allowed the completion of the first positron detector to study brain function.^{7,8} The earliest clinical applications were carried out in 1988 to diagnose cancers of the head-and-neck.

Copyright

©2014 Kitson SL. This is an open access article distributed under the Creative Commons Attribution 4.0 International License (CC BY 4.0), which permits unrestricted use, distribution, and reproduction in any medium, provided the original work is properly cited.

However, it was not until 1997 when approval was granted by the US Food & Drugs Administration that PET could be considered seriously as a major imaging tool.⁹ Subsequently, PET has become an established tool for the clinical assessment of head-and-neck cancers.¹⁰ In addition, PET imaging is being used to differentiate between benign and malignant tumours and is able to locate the metastases in the diseased organ, for example as in cancer of the lung.¹¹

PET radiotracers have been developed to study the role of dopamine and serotonin neurotransmission processes in the brain.¹² These radiotracers have probed the areas of the brain and Central Nervous System (CNS) for storage, re-uptake, post-synaptic binding and signaling mechanisms. Research continues to develop diagnostic imaging in the area of PET-immunology which target monoclonal antibodies towards tumor associated antigens. The design of PET ¹⁸F Reporter Probes such as Fluoropenciclovir (FPCV) has been developed to image Herpes Simplex Virus type-1 and thymidine kinase (HSV1-tk) for reporter expression.¹³ Other research areas include the use of PET imaging to track the transplantation of stem cells into diseased areas of myocardial infarction and also in Parkinson's disease.¹⁴ This enables the detection and monitoring of the functions of newly transplanted stem cells.

Currently, commercial multi-ring PET scanners have enhanced spatial resolution of detection with less than 5mm coupled with a greater sensitivity, axial coverage and increased image volume. The spatial resolution of PET is less than that of CT and MRI.¹⁵ This allows for whole-body PET studies to be carried out rapidly.¹⁶ The future role of PET imaging is pivotal in the organization of 'personalized medicine' by routinely screening and monitoring malignant disease states. According to *Ronald L van Heertum MD*¹⁷ of the University of Columbia, "PET is revolutionizing the fields of oncology, cardiology, neurology, and psychiatry, with a major impact on patient management."

PET NEURO-IMAGING

The basic principle of PET neuro-imaging is based on an assumption that high areas of radioactivity are related to brain activity.¹⁸ This activity can be evaluated by measuring the blood flow to various regions of the brain by administering the radiotracer [¹⁵O] oxygen. The disadvantage of using this radiotracer is its relatively short half-life of approximately 2 minutes. Therefore, on its output from the cyclotron it must be immediately transported and administered to the patient.¹⁹ In this article various radiotracers are discussed to circumvent these limitations in the diagnosis of Alzheimer's, Parkinson's, epilepsy and multiple sclerosis.

Alzheimer's disease

In Alzheimer's patients the PET-¹⁸FDG ([¹⁸F]fluoro-deoxyglucose) scans show a gradual deterioration of the brain

which leads to loss of memory and breakdown of cognitive thinking patterns.^{20,21} The diagnosis of Alzheimer's disease in patients can sometimes be made by carrying out a number of psychometric tests to evaluate the level of cognitive ability. PET-¹⁸FDG imaging can confirm a conclusive diagnosis of Alzheimer's disease.

PET-¹⁸FDG imaging of the brain may also be used to differentiate Alzheimer's disease from other dementia conditions. The most important consideration for the patient is an early diagnosis of the onset of Alzheimer's disease so treatment can be initiated as quickly as possible for the best outcome.²²

A range of positron radiotracers have been developed for PET imaging specifically towards neuro-receptor subtypes.²³ These PET radiotracers act as either agonists or antagonists to allow the visualization of neuro-receptor sites in particular neurological disease states. For example the radiotracer [¹¹C]PIB also called Pittsburgh Compound-B is a novel PET probe which helps in the visualization of beta-amyloid (A β) plaques in the brains of Alzheimer's patients.

PET amyloid plaque imaging with Pittsburgh Compound-B is shown to have a higher accumulation in subjects diagnosed with Alzheimer's disease compared to patients with no dementia. Most importantly, Pittsburgh Compound-B confirms the existence of A β plaques prior to the onset of dementia. This PET tracer is able to detect preclinical Alzheimer's disease pathology with the same accuracy as seen in post-mortem examinations.²⁴

In October 2013 the FDA gave approval to the amyloid ¹⁸F PET imaging agent Vizamy^l® (flutemetamol).²⁵ This imaging agent differs slightly from the other FDA approval (April 2012) of Amyvid[®] because it is used to evaluate the density of plaques using a colour-calibrated scale of signal intensity.

Consequently, Amyvid[®] was approved using a grayscale.²⁶ Amyvid[®], like Pittsburgh Compound-B binds to beta-amyloid. However due to its longer half-life of 110 minutes it was found to accumulate more in the brains of people with Alzheimer's disease, particularly in the regions known to be associated with beta-amyloid deposits.

Parkinson's disease

Dopamine is a 'phenethylamine' neurotransmitter and is produced in several areas of the brain including the *substantia nigra*. There are five types of dopamine receptors called D₁, D₂, D₃, D₄ and D₅. The PET radiotracer [¹⁸F]DOPA is widely used in the study of the dopaminergic system in movement disorders. [¹⁸F]DOPA is taken up by the terminals of dopaminergic neurons and converted to [¹⁸F]dopamine by the enzyme *dopa decarboxylase* and other dopamine metabolites.

PET imaging with [¹⁸F]DOPA can provide *in vivo* diagnostic information about the function of the pre-synaptic dopaminergic terminals. Other PET tracers that bind to pre-synaptic dopamine transporters include [¹¹C]methylphenidate and [¹¹C]dihydrotrabenzazine.²⁷

Parkinson's Disease (PD) is the result of loss of dopaminergic neurons in the *substantia nigra*. The greatest loss of neurons is seen in the *ventrolateral tier* of the *pars compacta*, with decreased involvement in the *dorsomedial tier*. The above regions can be detected by use of PET-[¹⁸F]DOPA to indicate the [¹⁸F]DOPA levels in the *putamen contralateral* area of the brain.²⁸

Epilepsy

The application of PET-¹⁸FDG imaging in epileptic patients is to determine the regions of the brain which show *epileptogenic foci*. PET imaging using the radiotracer ¹⁸FDG was first introduced in the 1980s to study epilepsy following the observation of regional glucose hypo-metabolism in patients with partial seizures. PET-¹⁸FDG can detect the epileptogenic regions in patients with *Temporal Lobe Epilepsy* (TLE) reducing the need for Electroencephalogram (EEG) studies. PET can also measure the binding of specific radiotracers to 'brain' receptors which contribute to the formation of seizures. For example serotonin 5-HT_{1A} receptor binding is shown to be decreased in TLE.²⁹ PET-¹⁸FDG, to date, compared to MRI remains the most sensitive, non-invasive imaging tool for temporal lobe seizures.³⁰

The PET radiotracer [¹¹C]flumazenil has been used to study the Benzodiazepine-receptor (BZD) in the role of epilepsy.³¹ These BZD receptors are situated in the same region as the γ -aminobutyric acid (GABA) receptors: the latter being the most important inhibitory neurotransmitters in the CNS. A reduction in [¹¹C]flumazenil binding has been observed at the mesial temporal lobe in TLE patients in the *amygdale* and *hippocampus* regions of the brain.

Multiple Sclerosis

The myelin PET radiotracer [¹¹C]MeDAS has been shown in animal models to penetrate the blood-brain barrier and therefore accumulate in regions of the brain indicating the presence of demyelination.³² Combinations of different PET radiotracers including [¹⁸F]FDG, [¹¹C]PK11195 and [¹¹C]MeDAS contribute to the characterization of individual lesions; monitoring of temporal changes in multiple sclerosis and evaluation of treatment responses.³³ A hybrid imaging approach using PET-MRI would provide a new approach to the formal diagnosis and treatment plan in patients with multiple sclerosis.³⁴

CONCLUSION

In the near future PET imaging will become a routine diagnostic tool for many underlying neurological diseases such as dementia and Parkinson's. PET imaging is playing a key role in the diagnosis of Alzheimer's disease from the development of the radiotracer Pittsburgh Compound-B used to detect amyloid plaques in the brain. The FDA approval of Vizamyli[®] and Amyvid[®] to evaluate the density of plaques in the progression of Alzheimer's disease has demonstrated the clinical application of PET neuro-imaging. Continued research and development in PET imaging will contribute to even earlier diagnosis of more disease states such as multiple sclerosis. This could potentially lead to a 'personalized medicine' culture which would be governed by our own genetic signature.

REFERENCES

1. Rontgen and the discovery of X-rays. *Br J Radiol.* 1995; 68(815): 1145-1176.
2. Flower MA. Webb's physics of medical imaging. *CRC Press*, 2012.
3. Cherry SR. The 2006 Henry N. Wagner lecture: of mice and men (and positrons) - advances in PET imaging technology. *J Nucl Med.* 2006; 47(11): 1735-1745.
4. Kitson SL, Cuccurullo V, Ciarmiello A, Salvo D, Mansi, L. Clinical applications of positron emission tomography (PET) imaging in medicine: oncology, brain diseases and cardiology. *Curr Radiopharm.* 2009; 2: 224-253.
5. Roß TL, Ametamey SM. PET chemistry: radiopharmaceuticals. In: Basic sciences of nuclear medicine. *Springer Berlin Heidelberg.* 2011; 103-118.
6. Cherry SR. Fundamentals of positron emission tomography and applications in preclinical drug development. *J Clin Pharmacol.* 2001; 41(5): 482-491. doi: [10.1177/00912700122010357](https://doi.org/10.1177/00912700122010357)
7. Nutt R. The history of positron emission tomography. *Mol Imaging Biol.* 2002; 1(4): 11-26. doi: [10.1016/S1095-0397\(00\)00051-0](https://doi.org/10.1016/S1095-0397(00)00051-0)
8. Brownell GL. A history of positron imaging. Website: <http://neurosurgery.mgh.harvard.edu/docs/PETHistory.pdf> 1999; Accessed March 15, 2014.
9. Hung JC, Callanhan RJ. USP and PET radiopharmaceuticals: 1997 FDAMA puts standard-setting body at center of regulatory process. *J Nucl Med.* 2004; 45(1): 13N-14N, 16N.

10. Klabbers BM, Lammertsma AA, Slotman BJ. The value of positron emission tomography for monitoring response to radiotherapy in head-and-neck cancer. *Mol Imaging Biol.* 2003; 4(5): 257-270.
11. Coleman RE, Hoffman JM, Hanson MW, Sostman HD, Schold SC. Clinical application of PET for the evaluation of brain tumors. *J Nucl Med.* 1991; 32(4): 616-622.
12. Lee C-M, Farde L. Using positron emission tomography to facilitate CNS drug development. *Trends Pharmacol Sci.* 2006; 27(6): 310-316. doi: <http://dx.doi.org/10.1016/j.tips.2006.04.004>
13. Jain M, Batra SK. Genetically engineered antibody fragments and PET imaging: A new era of radioimmunodiagnosis. *J Nucl Med.* 2003; 44(12): 1970-1972.
14. Beeres SLMA, Bengel FM, Bartunek J, et al. Role of imaging in cardiac stem cell therapy. *J Am Coll Cardiol.* 2007; 49(11): 1137-1148. doi: [10.1016/j.jacc.2006.10.072](http://dx.doi.org/10.1016/j.jacc.2006.10.072)
15. von Schulthess GK. Positron emission tomography versus positron emission tomography/computed tomography: From 'Unclear' to 'New-Clear' medicine. *Mol Imaging Biol.* 2004; 6(4): 183-187.
16. Surti S, Karp JS. Imaging characteristics of a 3-dimensional GSO whole-body PET camera. *J Nucl Med.* 2004; 45(6): 1040-1049.
17. Alavi A, Lakhani P, Mavi A, Kung JW, Zhuang H. PET: a revolution in medical imaging. *Radiol Clin of N Am.* 2004; 42(6): 983-1001.
18. Herholz K, Heiss W-D. Positron emission tomography in clinical neurology. *Mol Imaging Biol.* 2004; 6(4): 239-269.
19. Jones T, Rabiner EA. The development, past achievements, and future directions of brain PET. *J Cereb Blood Flow Metab.* 2012; 32(7): 1426-1454. doi: [10.1038/jcbfm.2012.20](http://dx.doi.org/10.1038/jcbfm.2012.20)
20. Venneri A. Imaging treatment effects in Alzheimer's disease. *Magn Reson Imaging.* 2007; 25(6): 953-968. doi: <http://dx.doi.org/10.1016/j.mri.2007.02.004>
21. Silverman DHS, Cummings JL, Small GW, et al. Added clinical benefit of incorporating 2-Deoxy-2-[18F]Fluoro-D-Glucose with positron emission tomography into the clinical evaluation of patients with cognitive impairment. *Mol Imaging Biol.* 2002; 4(4): 283-293.
22. Nordberg A. PET imaging of amyloid in Alzheimer's disease. *Lancet Neurol.* 2004; 3(9): 519-527. doi: [http://dx.doi.org/10.1016/S1474-4422\(04\)00853-1](http://dx.doi.org/10.1016/S1474-4422(04)00853-1)
23. Kitson SL. 5-Hydroxytyptamine (5-HT) receptor ligands. *Curr Pharma Design.* 2007; 13(25): 2621-2637. doi: [10.2174/138161207781663000#sthash.AYCWvomF.dpuf](http://dx.doi.org/10.2174/138161207781663000#sthash.AYCWvomF.dpuf)
24. Klunk WE, Engler H, Nordberg A. Imaging brain amyloid in Alzheimer's disease with Pittsburgh Compound-B. *Ann of Neurol.* 2004; 55(3): 306-319. doi: [10.1002/ana.20009](http://dx.doi.org/10.1002/ana.20009)
25. U.S. Food and Drug Administration Press Release. FDA approves second brain imaging drug to help evaluate patients for Alzheimer's disease, dementia, 2013. <http://www.fda.gov/newsevents/newsroom/pressannouncements/ucm372261.htm>; Accessed 2014.
26. U.S. Food and Drug Administration Press Release. FDA approves imaging drug Amyvid, 2012. <http://www.fda.gov/newsevents/newsroom/pressannouncements/ucm299678.htm>; Accessed 2014.
27. Björklund A, Dunnett SB. Dopamine neuron systems in the brain: an update. *Trends Neurosci.* 2007; 30(5): 194-202. doi: <http://dx.doi.org/10.1016/j.tins.2007.03.006>
28. Ravina B, Eidelberg D, Ahlskog JE, et al. The role of radiotracer imaging in Parkinson disease. *Neurology.* 2005; 64(2): 208-215.
29. Cliffe IA. A retrospect on the discovery of WAY-1000635 and the prospect for improved 5-HT1A receptor PET radioligands. *Nucl Med Biol.* 2000; 27(5): 441-447.
30. Kang KW, Lee DS, Cho JH, et al. Quantification of F-18 FDG PET images in temporal lobe epilepsy patients using probabilistic brain atlas. *Neuroimage.* 2001; 14(1 Pt 1): 1-6. doi: [10.1006/nimg.2001.0783](http://dx.doi.org/10.1006/nimg.2001.0783)
31. Bouvard S, Costes F, Bonnefoi F, et al. Seizure-related short-term plasticity of benzodiazepine receptors in parial epilepsy: a [11C]flumazenil - PET study. *Brain.* 2005; 128(Pt 6): 1330-1343. doi: <http://dx.doi.org/10.1093/brain/awh470>
32. Chunying Wu, Changing W, Daniela P, et al. A novel PET marker for in vivo quantification of myelination. *Bioorg Med Chem.* 2010; 18(24): 8592-8599. doi: [10.1016/j.bmc.2010.10.018](http://dx.doi.org/10.1016/j.bmc.2010.10.018)
33. Schroeter M, Dennin MA, Walberer M, et al. Neuroinflammation extends brain tissue at risk to vital peri-infarct tissue: a double tracer [11C]PK11195- and [18F]FDG-PET study. *J Cereb Blood Flow Metab.* 2009; 29(6): 1216-1225. doi: [10.1038/jcbfm.2009.36](http://dx.doi.org/10.1038/jcbfm.2009.36)
34. Riley C, Azevedo C, Bailey M, Pelletier. Clinical applications of imaging disease burden in multiple sclerosis. *Expert Rev Neurother.* 2012; 12(3): 323-333. doi: [10.1586/ern.11.196](http://dx.doi.org/10.1586/ern.11.196)