

Research

*Corresponding author

Alert José, MD

Department of Radiotherapy
Instituto Nacional de Oncología y
Radiobiología
Havana, Cuba

E-mail: jalert@infomed.sld.cu

Volume 2 : Issue 1

Article Ref. #: 1000NOJ2111

Article History

Received: May 20th, 2015

Accepted: August 11th, 2015

Published: August 12th, 2015

Citation

José A, Ivon C, Ricardo C, et al. Radiation therapy and nimotuzumab in children and adolescents with brainstem gliomas: a 5-year institutional experience. *Neuro Open J.* 2015; 2(1): 45-50. doi: [10.17140/NOJ-2-111](https://doi.org/10.17140/NOJ-2-111)

Copyright

©2015 José A. This is an open access article distributed under the Creative Commons Attribution 4.0 International License (CC BY 4.0), which permits unrestricted use, distribution, and reproduction in any medium, provided the original work is properly cited.

Radiation Therapy and Nimotuzumab in Children and Adolescents with Brainstem Gliomas: A 5-Year Institutional Experience

Alert José MD^{1*}, Chon Ivon MD¹, Cabanas Ricardo MD², Reno Jesus MD³, Garcia Debora MD³, Pérez Migdalia MD³ and Ropero Ramon MD⁴

¹Department of Radiotherapy, Instituto Nacional de Oncología y Radiobiología, Havana, Cuba

²Hospital Universitario, JM.Marques, Havana, Cuba

³Department of Oncopediatric, Instituto Nacional de Oncología y Radiobiología, Havana, Cuba

⁴Department of Clinical Research, Instituto Nacional de Oncología, Havana, Cuba

ABSTRACT

Background: Brainstem gliomas (BSG) are Central Nervous System (CNS) tumors with a median survival time of approximately 9 months. Up to now chemotherapy has not shown to improve survival in these patients. The outcome of Radiation Therapy (RT) in combination with Nimotuzumab is shown in the present report.

Material and Methods: 28 children and adolescents were included between Jan/2009 and Dec/2012 with the diagnosis of BSG and follow-up till January 2015. All patients had Diffuse infiltrative Pontine Gliomas (DIPG) and were irradiated with a dose ranging from 54 to 59.6 Gy at the National Oncology and Radiobiology Institute in Havana, Cuba. Three patients were planned with IMRT and 25 with 3D Conformal RT. Nimotuzumab was indicated at the dose of 150 mg/m² weekly during the time of RT treatment, then every 15 days during 8 weeks and finally monthly for 1 year. Univariate and multivariate Cox regression models and Kaplan Meier survival were analyzed to evaluate the survival.

Results: Median age at diagnosis was 7 years (range 3-18 years old), median overall survival was 17.3 months (95% CI 14.0-20.5) since the beginning of the treatment and the accumulated survival at 5 years of treatment was 42,9%. There was balance in sex, age and dosage of RT in the population. Addition of Nimotuzumab to RT was safe.

Conclusions: The combination of Radiotherapy and Nimotuzumab were well tolerated in this brainstem tumours patient's series.

KEYWORDS: Radiotherapy; Nimotuzumab; Brainstem tumors children adolescents.

ABBREVIATIONS: BSG: Brainstem gliomas; CNS: Central Nervous System; RT: Radiation therapy; DIPG: Diffuse infiltrative Pontine Gliomas; ChT: Chemotherapy; INOR: National Oncology and Radiobiology Institute; CTV: Clinical Target Volume; GTV: Gross Tumour Volume; PTV: Planning Target Volume.

INTRODUCTION

The brainstem is defined as the midbrain, pons and medulla; brainstem gliomas are generally diffuse intrinsic tumors involving the pons, with defined clinical presentation and characteristic appearance in imaging findings and do not require pathological confirmation;¹⁻⁴ it can extend along neural tracts to adjacent regions of the brain, so it has been defined as fatal disease. Radiation treatment response rates show low degrees of efficacy, with short-term responses and a median overall survival less than one year;²⁻⁸ Diffusely infiltrating pontine gli-

mas must be distinguished from other subsets of diffuse intrinsic pontine gliomas, such as focal tumors, which are described with better prognosis and longer term survival.^{5,9}

The association of Chemotherapy (ChT) and radiotherapy (RT) have not improved survival^{1,6-8,10,11} and now biologics are combined with RT in clinical trials.^{9,12,13}

We investigated the association of RT with Nimotuzumab, a humanized monoclonal antibody developed at the Center of Molecular Immunology, Havana, Cuba and testing the hypothesis that this combination will improve survival in these tumors. The antibody was obtained by humanization of the murine antibody EGF/R3.¹⁴ Because Nimotuzumab has a 10 fold lower affinity to the EGFR, as compared to cetuximab, its capacity to bind EGFR is heavily dictated by cell receptor density.¹⁵ Nimotuzumab preclinical and clinical characterizations have been summarized before.¹⁶⁻¹⁸

A distinguishing feature of Nimotuzumab compared to other mAbs of the EGFR class is the lack of severe skin toxicity and the possibility to be used beyond progression.^{16,19}

MATERIAL AND METHODS

We conducted a prospective, non-randomized clinical study, with a treatment group of 28 children and adolescents (range 3 to 18 years) with the diagnosis of diffuse intrinsic pontine glioma (DIPG) documented by imaging (MRI, CT scan.) Biopsy and histology confirmation were not a requirement of this study. This study covers a sequential period between Jan/2009 and Dec/2012. Follow-up continued to September 2014. Patients with focal lesion of the brainstem were not eligible for the study, because these are described with a better prognosis.^{5,9} Also excluded were those who had received prior chemotherapy or radiotherapy.

The study was approved by the Ethical Institution Committee at the National Oncology and Radiobiology Institute (INOR), Havana and informed consent obtained from the patients' parents. All patients were irradiated at INOR, and received the monoclonal antibody Nimotuzumab at INOR or at the Pediatric Hospital "Juan Manuel Marques", also in Havana. Male patients: 14, and female: 14.

No surgical treatment was feasible, and in 3 there were pathologic results by biopsy. In all patients tumor was extended to the pons.

Linear Accelerator was used for a radiation treatment: Gross Tumour Volume (GTV) was defined as the visible tumor, either by MRI or CT; Clinical Target Volume (CTV) accounted for subclinical microscopic disease and unappreciated tumor extension, generally 1.5 cm from the GTV, and Planning Target Volume (PTV) was 0.3-0.5 cm and could vary according to the Organ at Risk.^{4,20} RT doses range from 54 to 59.8 Gy, with dose

per fraction 1,8 Gy. Three patients were planned with IMRT and the rest with 3D CT. In all patients a thermoplastic mask was fitted.

Nimotuzumab was administered at a dose of 150 mg/m² (IV), weekly during the term of RT, then every 2 weeks for 8 doses, then monthly for one year. In the last patients included it was prolonged for 2 years.

Twenty four patients (85.7%) received the complete Nimotuzumab schema, in 4 there were minor interruptions of the dosage because patients did not concur with the treatment option in a timely manner. Characters of the series are in Table 1.

Median age at diagnosis.....	7 years old (range 3-18 years)
Male/female ratio.....	1:1
Type of tumor.....	DIPG:28
Localization.....	Mid brain and pons: 15
	Pons:6
Cerebello-pontine: 4	
Not specified: 3	
Pathology.....	Grade II Astrocytoma:2
	Grade III Astrocytoma: 1
Not biopsied: 25	
Radiotherapy dose received.....	54-57 Gy : 4 patients
	57-59 Gy: 15 patients
	59, 8 Gy: 9 patients
Nimotuzumab treatment.....	Completed: 24
	Not completed: 4

Table 1: Charts of the series of brainstem gliomas in children and adolescents.

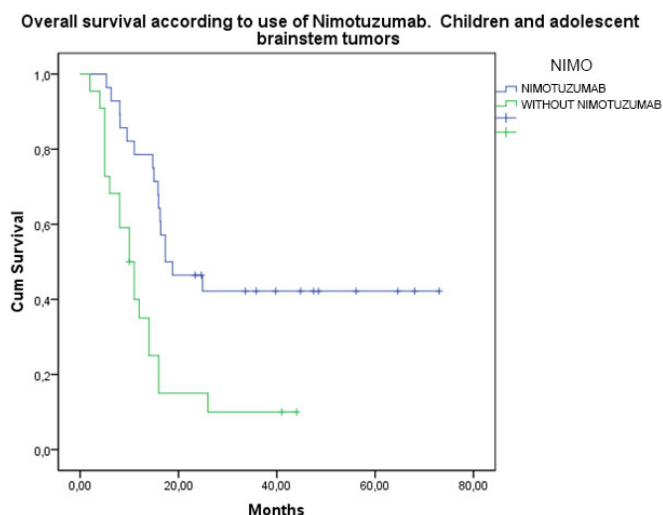
Univariate and multivariate Cox regression models were fitted in order to identify possible predictors of survival and Kaplan Meier survival was calculated for all cases.

RESULTS

Median age of the cases at diagnosis was 7 years (range between 3 and 18 years old). Twenty eight cases were DIGP, but in all cases tumor extended to pons, and in one case also to 4th ventricle, cerebellum and hypothalamus.

The diagnosis was made by clinical and imaging findings except in 3 cases where pathological examination was also done, one with astrocytoma grade II and the 2 others with astrocytoma grade III, all alive. Median overall survival from the beginning of treatment was 17,3 months, 95% CI (14.1-20.7) and Kaplan Meier survival accumulated was 42,9% at 2 years, established till 5 years of RT treatment. At present, (January

2015) 12 of the patients are alive (2 less than 2 years, 3 between 2-3 years, 5 between 4-5 years and 2 with more than 5 years of follow-up). Therapeutic results were compared with a previous case series of 22 children and adolescents with BSG treated with the same mode of irradiation, but without Nimotuzumab during 1992-2008 at the same institution (Instituto Nacional de Oncología y Radiobiología in Havana.) (Figure 1)



NIMO	Median		
	Estimate	95% Confidence Interval	
		LowerBound	UpperBound
RT + NIMOTUZUMAB	17,333	14,068	20,599
RT	10,000	7,422	12,578
Overall	15,833	12,380	19,286

Figure 1: Survival according to treatment: a) 28 patients treated with Radiotherapy (RT) and Nimotuzumab, with a median overall survival of 17,3 months (95% CI 14.0-20.5) and accumulated survival of 42,9% at 5 years. b) Previous serie of 22 patients trated only with RT, with a median overall survival of 10 months (95% CI 7.4-12.5), with no survival accumulated at 5 years. P=0,001.

Sex

14 female patients had a 44.0% survival at 2 years and counting, and 14 male patients a 33.3 % survival. (Figure 2)

Five patients received a dose between 54-57 Gy, with a survival rate of 60% at 2 years and counting; 16 patients with a dose between 57-59 Gy with a survival rate of 41,2 % at 2 years plus, and 7 patients received 59.8 Gy with a survival rate of 22.2% at 2 years plus. Radiation dose was increased in those patients where DIPG tumor size exceeded the mean. (Figure 3)

By Age Group

6 patients in the group up to 4 years old (21.5%) with a survival rate of 25% at 2 years plus; 15 patients between 5-9 years old (53.6%) with a survival rate of 37.5% at 2 years plus; 4 patients between 10-14 years old (14.4%) with a survival rate of 67%; and 3 patients with 15-18 years old age (10.7%) with a survival rate of 50% at 2 years plus (Figure 4).

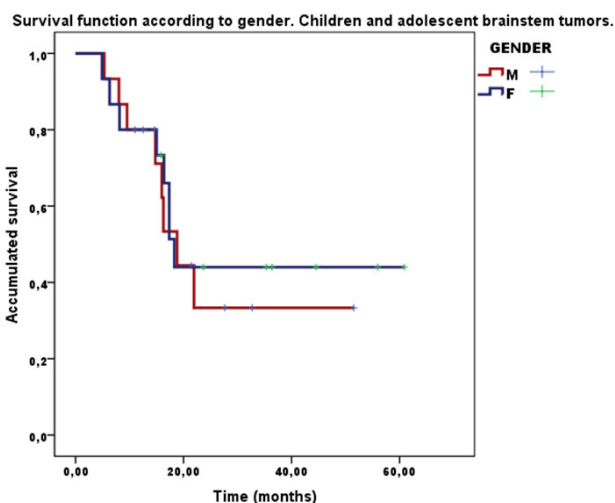


Figure 2: Survival function according to gender. 14 female patients, 44% survival at two years; 14 male patients patients, 33,3% survival at two years. No differences p=0.74.

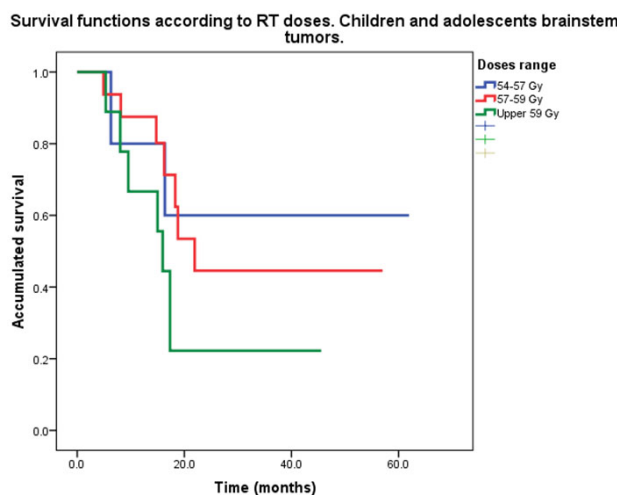


Figure 3: Survival functions according to Radiotherapy (RT) doses: 5 patients received dose between 54-57 Gy with a survival rate of 60%; 16 patients with dose between 57-59 Gy with a survival rate of 41,2%, and 7 patients received 59,8 Gy with a survival of 22,2%; p=0,254.

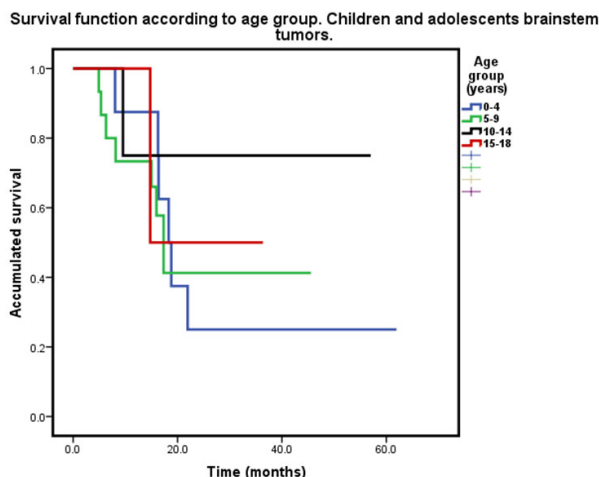


Figure 4: Survival according to age group: 6 patients up to 4 years old with a survival rate of 25 %; 15 between 5-9 years old with a survival rate of 37,5%; 4 patients between 10-14 years old with a survival of 68% and 3 with 15-18 years old and a survival rate of 50%; p=0.777.

Multivariate analysis showed no significant differences according to sex, age and dose of irradiation received, nor with the dosage of Nimotuzumab, with a tendency for best survival in age group 10-18 years old and with the dose at 54-57 Gy.

Treatment was well tolerated and no grade III or higher grade toxicity was observed. The most frequent adverse event was alopecia in irradiation fields, observed in 27 patients (96.4%). Other reported adverse events were vomiting, headache, fever, tremor and nausea, in less than 40% of patients (Table 2).

Most frequent related adverse events				
Severity grade:	1	2	3	4
Vomiting	5	3	0	0
Headache	3	1	0	0
Fever	3	0	0	0
Tremor	0	2	0	0
Nausea	2	0	0	0

Table 2: Severity grade goes from 1 (less severe) to 4 (most severe).

At the end of irradiation there was a clinical response in 27 patients (96.4 %), only one patient had no response to RT treatment.

DISCUSSION

Brainstem gliomas are a heterogeneous group of tumors that occur predominately in children, have a characteristic appearance in MRI and CT and do not require pathological confirmation: clinical and imaging are considered sufficient for diagnosis;^{1-4,21} they have a bad prognosis despite initial response to irradiation, which has been the ideal treatment, with a median survival of one year or less.^{1-3,5,12,21} Radiation dose escalation increases toxicity but does not improve outcome; neither chemotherapy nor hypofractionation^{4,21-24} have improved therapeutic ratio.

Brainstem gliomas could be diffuse intrinsic pontine gliomas (DIPG) and comprise an entity defined by imaging involving pons. Pontine localization was found to be a negative prognostic factor.⁵ Two more recent studies did not demonstrate similar findings;^{25,26} these studies included adult patients, possibly confounding results. In our series, we found pontine infiltration in all patients.

Our series of 28 children and adolescents with prolonged treatments involving Nimotuzumab in conjunction with RT showed a median overall survival of 17.3 months and a survival rate at 2 years of 39.7%, exceeding those of earlier reports,^{2,24,27} and of more recent ones.^{1,3,5,12,28-34} In a previous case series of patients treated only with RT during the period 1992-2008 in the same Institution (National Oncology and Radiobiol-

ogy Institute, in Havana), median survival time was 10.0 months and the survival rate at 2 years was 15%. We know that the use of retrospective case series as control groups have limitations, but there are facts that are relevant: all cases were irradiated in the same Institution, so there could not exist center-effects that could bias patient groups.

It is remarkable that in our series there is a preliminary benefit to survival in older ages; it contrasts with reports that young age may predict a better outcome for children with diffuse pontine gliomas.³⁴ Best results were obtained in the group that received 54-57 Gy of RT dosage; increasing RT dosage did not yield better results, consistent with.^{22,30}

The prolonged use of Nimotuzumab for one year or more was well tolerated: adverse events such as alopecia and dermatitis were related to irradiation. Cutaneous rash was also reported but not related; other minor adverse events could be related in part with the clinical evolution of the tumor and the radiation treatment. Nimotuzumab is a humanized monoclonal antibody that recognizes the EGF external domain with intermediate affinity ($K_d=10^{-8}$)³⁵ that has shown a benefit in addition to RT in different studies.³⁵⁻³⁷ In children it has been reported with good results and safely associates to RT in CNS and Head and Neck tumors.^{2,31-44}

CONCLUSION

The association of focal RT and Nimotuzumab in the treatment of brainstem tumors in children and adolescents was a therapeutic option in order to increase overall survival and support the possibility of new trials with this combination. Radiation dose over 57 Gy did not increase possibilities of survival in our series.

CONFLICTS OF INTEREST

No potential conflict of interest exists.

REFERENCES

- Bailey S, Howman A, Whealtes K, et al. Diffuse intrinsic pontine glioma treated with prolonged Temozolomide and Radiotherapy. Results of a United Kingdom phase II trial (CNS 2007 04). *Eur. J. Cancer.* 2013; 49: 3856-3862. doi: [10.1016/j.ejca.2013.08.006](https://doi.org/10.1016/j.ejca.2013.08.006)
- Blaney S, Kun L, Hunter J, et al. Tumor of the Central Nervous System. In: Pizzo P, Poplack, ed. *Principles and Practice of Pediatric Oncology*. 5th. Ed. Lippincott Williams & Wilkins, Philadelphia, USA, 2006; 786-864.
- Wolff JE, Rytling M, Vats T, et al. Induction treatment for diffuse intrinsic pontine glioma. Experience of M.D. Anderson

- Cancer Center. *Anticancer Res.* 2011; 31: 2265-2270.
4. Marcus K, Dutton SH, Barnes P, et al. A phase I trial of Etanidazole and hyperfractionated radiotherapy in children with diffuse brainstem gliomas. *Int J Radiat Oncol Biol Phys.* 2013; 55: 1182-1185. doi: [10.1016/S0360-3016\(02\)04391-2](https://doi.org/10.1016/S0360-3016(02)04391-2)
5. Fried I, Hawkins C, Scheinmann K, et al. Favorable outcome with conservative treatment for children with low-grade brainstem tumors. *Pediatr Blood & Cancer.* 2012; 58: 556-560. doi: [10.1002/pbc.23200](https://doi.org/10.1002/pbc.23200)
6. Hargrave D, Bartels V, Bouffet E. Diffuse brainstem gliomas in children: critical review of clinical trial. *Lancet Oncol.* 2006; 7: 241-248. doi: [10.1016/S1470-2045\(06\)70615-5](https://doi.org/10.1016/S1470-2045(06)70615-5)
7. Jansen MH, van Vuurden DG, Vandertop WP, et al. Diffuse intrinsic pontine gliomas: a systematic update on clinical trials and biology. *Cancer Treat Rev.* 2012; 38: 27-35. doi: [10.1016/j.ctrv.2011.06.007](https://doi.org/10.1016/j.ctrv.2011.06.007)
8. Frazier JL, Lee J, Thomale UW, et al. Treatment of diffuse intrinsic brainstem gliomas. Failed approaches and future strategies. *J Neurosurg.* 2009; 3: 259-269. doi: [10.3171/2008.11.PEDS08281](https://doi.org/10.3171/2008.11.PEDS08281)
9. Minturn JE, Fisher MJ. Gliomas in children. *Current Treat Options Neurol.* 2013; 15: 316-327.
10. Chassot A, Canale S, Varlet P. Radiotherapy with concurrent and adjuvant Temozolamide in children with newly diagnosed intrinsic pontine gliomas. *J Neurooncol.* 2012; 106: 399-407. doi: [10.1007/s11060-011-0681-7](https://doi.org/10.1007/s11060-011-0681-7)
11. Cohen KJ, Heideman RL, Zhou T. Temozolamide in the treatment of children with newly diagnosed diffuse intrinsic pontine gliomas: a report from the Children's Oncology Group. *Neurooncol.* 2011; 13: 410-416. doi: [10.1093/neuonc/noq205](https://doi.org/10.1093/neuonc/noq205)
12. Janssens G, Jansen M, Launers G, et al. Hypofractionated conventional radiation therapy for newly diagnosed diffuse intrinsic pontine gliomas: a matched cohort analysis. *Int J Radiation Oncol Biol Phys.* 2013. doi: [10.1016/j.ijrobp.2012.04.006](https://doi.org/10.1016/j.ijrobp.2012.04.006)
13. Solomon MT, Selva JC, Figueredo J, et al. Radiotherapy plus Nimotuzumab or placebo in the treatment of high grade glioma patients: results from a randomized, double blind trial. *BMC Cancer.* 2013; 299. doi: [10.1186/1471-2407-13-299](https://doi.org/10.1186/1471-2407-13-299)
14. Fernandez A, Spitze E, Perez R, et al. A new monoclonal antibody for detection of EGF receptors in western blots and paraffin-embedded tissue sections. *J Cell Biochem.* 1992; 49: 152-165.
15. Garrido G, Tikhomirov IA, Rabasa A, et al. Bivalent binding by intermediate affinity of Nimotuzumab: a contribution to explain antibody clinical profile. *Cancer Biol Ther.* 2011; 11: 373-382.
16. Boland WK, Bebb G. Expert opinion, nimotuzumab, a novel anti-EGFR monoclonal antibody that retains anti-EGFR activity while minimizing skin toxicity. *Expert Opin Biol Ther.* 2009; 9: 1199-1206. doi: [10.1517/14712590903110709](https://doi.org/10.1517/14712590903110709)
17. Lam C, Bouffet F, Bartels U. Nimotuzumab in pediatric glioma. *Future Oncol.* 2009; 5: 1349-1361. doi: [10.2217/fon.09.119](https://doi.org/10.2217/fon.09.119)
18. Massimino M, Bode U, Bassani V, et al. Nimotuzumab for pediatric diffuse intrinsic pontine gliomas. *Expert Opin Biol Ther.* 2011; 11: 247-256. doi: [10.1517/14712598.2011.546341](https://doi.org/10.1517/14712598.2011.546341)
19. Rivera F, Vega-Villegas ME, Lopez-Brea MF, et al. Current situation of Pantumumab, Matuzumab, Nimotuzumab and Zalutumumab. *Acta Oncol.* 2008; 47: 9-19. doi: [10.1080/02841860701704724](https://doi.org/10.1080/02841860701704724)
20. Chon I, Chi D, Alert J, et al. Transition from 2D to 3D Conformal Radiotherapy in high grade gliomas: our experience in Cuba. ICARO, Vienna April 2009. Book of extended synopsis. 38-39, IAEA-CN-170-2009.
21. Jallo GI, Biser-Rohrbaugh A, Freed D. Brainstem gliomas. *Childs Nerv Syst.* 2004; 20: 143-153.
22. Freeman CR, Krischer JP, Sanford RA. Final results of a study of escalating doses of hyperfractionated radiotherapy in brainstem tumors in children: a Pediatric Oncology Group Study. *Int J Radiat Oncol Biol Phys.* 1993; 27: 197-206. doi: [10.1016/0360-3016\(93\)90228-N](https://doi.org/10.1016/0360-3016(93)90228-N)
23. Fangusard J. Pediatric high-grade gliomas and Diffuse Intrinsic Pontine Gliomas (DIPG). *J Child Neurol.* 2009; 24: 1409-1417. doi: [10.1177/0883073809338960](https://doi.org/10.1177/0883073809338960)
24. Negretti L, Bouchireb K, Levy-Piedbois C, et al. Hypofractionated radiotherapy in the treatment of diffuse intrinsic pontine gliomas in children: a single institution's experience. *J Neuro-oncol.* 2011; 104:773-777.
25. Ueoka DL, Nogueira J, Campos JC, et al. Brainstem gliomas-retrospective analysis of 86 patients. *J NeuroSci.* 2009; 281: 20-23. doi: [10.1016/j.jns.2009.03.009](https://doi.org/10.1016/j.jns.2009.03.009)
26. Combs SE, Steck I, Schulz-Ertner D, et al. Long-term outcome of high-precision radiotherapy in patients with brainstem gliomas. Results from a difficult-to-treat population using fractionated stereotactic radiotherapy. *Radiother Oncol.* 2009; 91: 60-66. doi: [10.1016/j.radonc.2009.02.012](https://doi.org/10.1016/j.radonc.2009.02.012)
27. Freeman CR, Suissa S. Brainstem tumors in children: results of a survey of 62 patients treated with radiotherapy. *Int J Radiat Oncol Biol Phys.* 1986; 12: 1823-1828. doi: [10.1016/0360-3016\(86\)90325-1](https://doi.org/10.1016/0360-3016(86)90325-1)

28. Kabudi R, Cafir FB, Agaoglu FY, et al. Pediatric diffuse intrinsic pontineglioma patients from a single center. *Childs Nerv Syst.* 2013; 29: 583-588. doi: [10.1007/s00381-012-1986-3](https://doi.org/10.1007/s00381-012-1986-3)
29. Kabudi R, Cafir FB. Management of diffuse pontineglioma in children: recent development. *Paediatr Drugs.* 2013; 5: 351-362. doi: [10.1007/s40272-013-0033-5](https://doi.org/10.1007/s40272-013-0033-5)
30. Panoff JE, Koru-Sengul T, Khatib Z. The role of Radiation Therapy technique and dose for pediatric patients with diffuse intrinsic pontineglioma. *Int J Radiat Oncol Biol Phys.* 2013; 87: S594-S595.
31. Kabudi R, Cafir FB, Agaoglis D. Diffuse Intrinsic Pontine Gliomas (DIPG) in children: results from a single center. *Neuro-oncol.* 2012; 14: 29.
32. Zapotocky M, Churackova M, Malinova B, et al. Chemotherapy added to Radiotherapy failed to improve outcome of children with DIPG: single institution experience. *Neuro-oncol.* 2012; 14: 30.
33. Nolre L, Vasconcelos F, Lima F, et al. Pediatric brainstem glioma: experience of one Brazilian Institution. *Neuro-oncol.* 2012; 14: 16.
34. Broniscer A, Laningham FH, Sanders RP, et al. Young age may predict a better outcome for diffuse pontineglioma. *Cancer.* 2008; 113: 566-572. doi: [10.1002/cncr.23584](https://doi.org/10.1002/cncr.23584)
35. Osorio M, Cruz T, del Castillo R, et al. Nimotuzumab plus Radiotherapy for unresectable squamous-cell carcinoma of the Head and Neck. *Cancer Biol & Ther.* 2010; 9: 343-349.
36. Ramos Suzarte M, Lorenzo Luaces P, Lazo N, et al. Treatment of malignant, non-resectable epithelial origin esophageal tumors with the humanized antiepidermal growth factor antibody Nimotuzumab combined with radiation therapy and chemotherapy. *Cancer Biol & Ther.* 2012; 13: 1-6.
37. Liang J, Mingzam E, Gang W, et al. Nimotuzumab combined with radiation therapy on esophageal cancer. Preliminary study of Phase 2 Clinical Trial. *Int J Radiat Oncol Biol Phys.* 2013; 87: S292. doi: [10.1016/j.ijrobp.2013.06.765](https://doi.org/10.1016/j.ijrobp.2013.06.765)
38. Cabanas R, Suarez G, Crombet T, et al. Safety and efficacy results of children and adolescents Central Nervous System Tumor. Nimotuzumab expanded access program. *Ped Blood & Cancer.* 2011; 57: 705-897.
39. Crombet T, Cabanas R, Alert J, et al. Nimotuzumab and Radiotherapy in children and adolescents with brainstem gliomas: preliminary results from a phase II Study. *European J Cancer.* 2009; 7: 4974.
40. Cabanas R, Crombet T, Alert J, et al. Nimotuzumab in children and adolescents with brainstem tumors: a Phase II study. *Ped Blood & Cancer.* 2009; 59: 830-831.
41. Alert J, Reno J, Garcia D, et al. Three dimensional Conformal Radiotherapy concurrent with chemotherapy plus Nimotuzumab in the treatment of Head and Neck cancer in children and adolescents: experience in a single institution. *Ped Blood & Cancer.* 2012; 59: 94.
42. Bude U, Buchen S, Warmouth-Metz, et al. Final report of phase II trial of Nimotuzumab in the treatment of refractory and relapsed high grade gliomas in children and adolescents. ASCO Meeting. *J Clin Oncol.* 2007; 25.
43. Massimino M, Biassoiri V, Gandola I, et al. Nimotuzumab and Vinorelbine concomitantly to radiation and as a maintenance for diffuse pontineglioma in childhood: results from a serie of 12 patients. *J Clin Oncol.* 2011; 26: 9577.
44. Cabanas R, Saurez G, Alert J, et al. Prolonged use of nimotuzumab in children with central nervous system tumors: safety and feasibility. *Biother Radiopharm.* 2014; 29: 173-178.