

Short Communication

Replantation: Is the Glory Well Deserved?

Pooja Kapoor MDS¹; Harpreet Singh MDS^{2*}; Jagvinder Singh Mann MDS³

Department of Orthodontics and Dentofacial Orthopaedics, MN DAV Dental College and Hospital, Solan, HP, India

Department of Conservative Dentistry and Endodontics, MN DAV Dental College and Hospital, Solan, HP, India

Department of Conservative Dentistry and Endodontics, Government Dental College and Hospital, Patiala, Punjab, India

*Corresponding author

Harpreet Singh MDS

Professor and Head, Department of Conservative Dentistry and Endodontics, MN DAV Dental College and Hospital, Solan, HP, India

E-mail: hsgentledental@gmail.com

Article information

Received: April 10th, 2018; Revised: May 17th, 2018; Accepted: May 18th, 2018; Published: July 2nd, 2018

Cite this article

Pooja K, Harpreet S, Jagvinder SM. Replantation: Is the glory well deserved? *Dent Open J*. 2018; 5(1): 30-33. doi: [10.17140/DOJ-5-139](https://doi.org/10.17140/DOJ-5-139)

ABSTRACT

Avulsed teeth comprise 1-16% of all traumatic injuries of the permanent dentition. Individuals with a greater overjet are known to be more at risk compared with individuals who have a normal overjet. Unfortunately, in these situations, intrepid calculative decisions must often be made quickly, because the loss of a maxillary central incisor classically occurs by accident most commonly in patients with Angles' Class II division 1 malocclusion. Various long-term solutions considered for avulsed maxillary incisors, especially in patients requiring orthodontic treatment at a later date are considered here along with clinical cases. Trauma often leaves extensive defects rendering the scope of implants almost nil at the concerned area and some round tripping of drifted teeth in the edentulous area can be used as an advantage for orthodontic site development to accept future prosthesis.

Keywords

Avulsed; Ankylosis; Reimplantation; Permanent tooth; Dentoalveolar trauma; Prognosis.

INTRODUCTION

The orthodontic practitioner often encounters patients who have traumatically avulsed maxillary central incisors in daily practice.¹⁻⁷

According to American Academy of Pediatric Dentistry, 'Avulsion' is the "complete displacement of a tooth out of its socket." The periodontal ligament is torn mostly accompanied by alveolar fracture.⁸ Of all the traumatic injuries involving permanent dentition, avulsed teeth encompass 1-16%.⁹ People having more than normal overjet are known to be at double the risk as compared to those who have a normal overjet.^{10,11} Unfortunately, in these situations, certain decisions ought to be made hurriedly as incisor avulsion classically takes place by accident most commonly in these patients.¹²⁻¹⁵

In such a situation, the straightforward and lasting way out considered is to reimplant it, the success depending on tooth root,¹⁴ endodontics performing ability¹ and the time lapsed since avulsion.¹⁶ Complications after replantation are commonly encountered with the prevalence rate being 55% to 85%.^{17,18} Also, ankylosis, extreme movement within socket, internal and external

resorption might crop up through the next few years. Many of these teeth do not last beyond 5 to 7 years even after a root canal therapy.¹

If avulsed tooth is lost/damaged, autotransplantation can be done in patients with tooth size arch length discrepancy,¹⁹⁻²⁵ as typically seen in the Class II cases. Here, a premolar is relocated to the edentulous site, negating the need for premolar camouflage extractions at a later date. However, premolar roots should be formed between one-half and two-thirds. In best possible circumstances, auto-transplantation might be less successful with a surgeon who is not experienced in the procedure.

A third probable resolution is to close the edentulous space by using the ipsilateral lateral incisor as a replacement for the avulsed central.²⁶

Fourth way out can be the maintenance of the edentulous space by constructing a temporary removable prosthesis to address the patient's immediate functional and esthetic needs, to be

restored later by an implant or bridge during adulthood. Evidence suggests that upon extracting teeth in growing patients, although alveolar thickness narrows down from 25% to 30%, perpendicular alveolar height of the edentulous ridge catches up speed with the contiguous erupting teeth.²⁷ But in these patients with prominent premaxillae, the alveolus does not get the stimulus in missing incisor area for deposition and resorption. Therefore, lateral incisor or the contralateral central incisor has to be moved mesially (or allowed to move by drifting gradually in edentulous space due to pull of the transseptal fibres) such that, it brings about bone remodeling when retracted orthodontically for overjet reduction. Space is reopened after remodeling to accept implant/prosthesis.

CASES

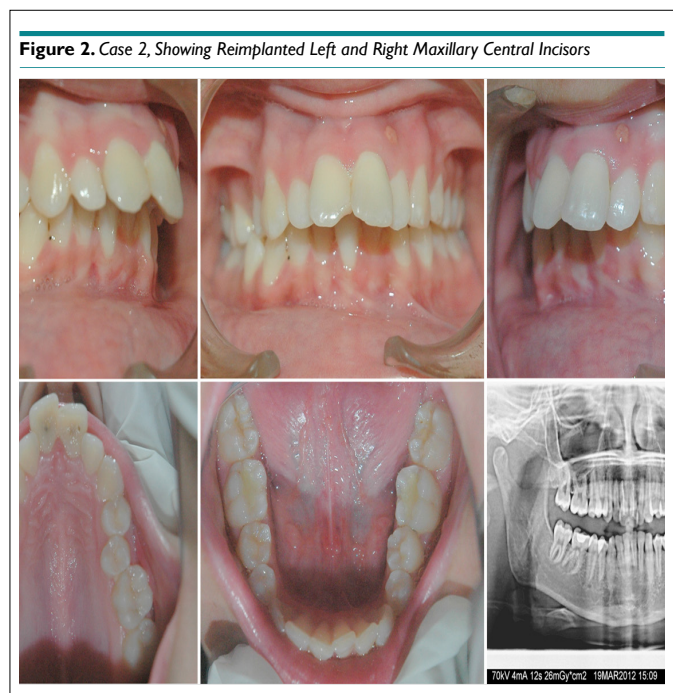
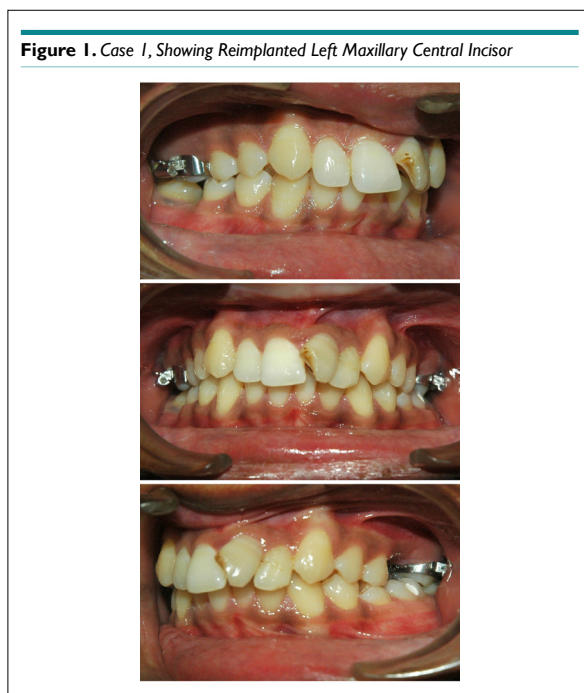
Illustrated here are two examples (Case I and Case II, one of them pursuing Orthodontics as a career). Prior to the proceedings, patients illustrated in Case I: Figure 1 and Case II: Figure 2 signed the consent forms. These patients were, unfortunately, not monitored by the dentist on a regular basis. On a visit to the Orthodontic

clinic while seeking alignment of teeth, the reimplanted teeth were found to have ankylosed. These teeth generally do not respond to orthodontic therapy, even after using stronger eruptive forces and luxation. Periapical radiographs show extensive root resorption, no periodontal membrane remaining or periapical lesions and the teeth have to be ultimately extracted. Owing to the deficient incisor, the consequent alveolar defect is extensive which renders this site tough unfavorable for restoration by implants.

DISCUSSION

Reimplanted teeth might ankylose. Evidently, such a tooth does not erupt creating a substantial perpendicular deficiency that magnifies further in a growing patient. Such a defect would not have occurred if this tooth was extracted earlier and treatment plans alternate to reimplantation discussed earlier were implemented.

Although ankylosed roots can be moved upon luxation, they may never erupt due to absence of periodontal ligament.²⁸ In such patients, distraction of alveolar segments might be a better



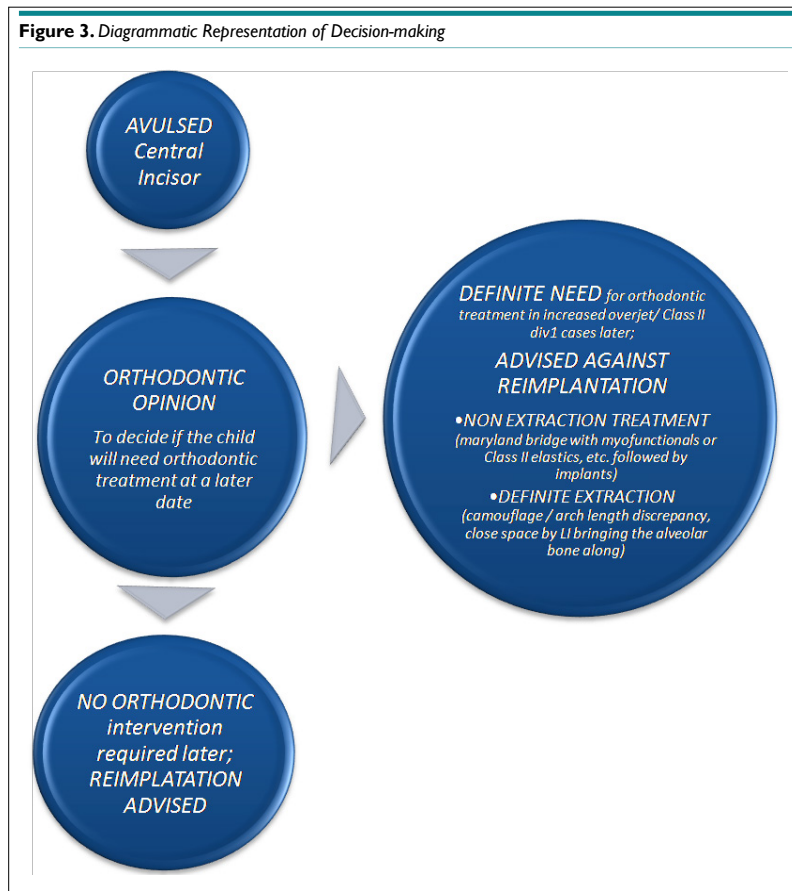option for making such teeth erupt.²⁹

However, as in Case I with rotated tooth and large periapical lesion, prognosis is poor. The assessment of an alternative for the space in question turns out to be the instantaneous apprehension of the suffering child and his/her family along with the concerned dentist or orthodontist. A classic way out is to construct a temporary removable prosthesis to aid in perking up both aesthetics and function.

A distinct advantage can be obtained at times by leaving the area as such without any immediate replacement. Sometimes, the erupting teeth drift bodily in growing children bringing the al-

veolar bone along with. However, in adults, teeth generally tilt or incline towards each other rather than drifting bodily as the growth is complete. In children, various treatment options can be explored by regaining space for inserting an implant or bridge pontic, or substituting the central incisor by a lateral incisor.

Space regainers act by pushing apart the drifted teeth like lateral incisor and contralateral central incisor, resulting in creating fresh alveolar bone in the developing edentulous space with a similar thickness to the root width as surrounding teeth. This process is called orthodontic site development. Evidence suggests that this buccolingual alveolar thickness does not resorb or narrow down.³⁰ Such sites offer improved bone vertically as well as labiolingually



for receiving the final prosthesis. Preserving edentulous space as such during transition from mixed to permanent dentition results in deficient alveolar thickness that might require bone or a soft-tissue grafting prior to any restoration.

CONCLUSION

Timely supervision and treatment of patients with traumatic avulsion was discussed for guidance in prevention of extensive defects which render the scope of implants almost nil at the concerned area. Some round tripping of drifted teeth in the edentulous area can be used as an advantage for orthodontic site development to accept future prosthesis (Figure 3).

CONFLICTS OF INTERESTS

The authors deny any conflicts of interest.

CONSENT

An informed consent was taken from the patient

REFERENCES

1. Trope M. Avulsion and replantation. *Refuat Hapeh Vehashinayim*. 2002; 19(2): 6-15.
2. Andreasen JO, Andreasen FM, Andersson L. *Textbook and Color*

Atlas of Traumatic Injuries to the Teeth. 4th ed. Oxford, UK: Blackwell Munksgaard; 2007.

3. Tzigkounakis V, Merglova V, Hecova H, et al. Retrospective clinical study of 90 avulsed permanent teeth in 58 children. *Dent Traumatol*. 2008; 24(6): 598-602. doi: [10.1111/j.1600-9657.2008.00674.x](https://doi.org/10.1111/j.1600-9657.2008.00674.x).
4. Glendor U. Epidemiology of traumatic dental injuries-a 12 year review of the literature. *Dent Traumatol*. 2008; 24(6): 603-611. doi: [10.1111/j.1600-9657.2008.00696.x](https://doi.org/10.1111/j.1600-9657.2008.00696.x).
5. Ivancic Jokic N, Bakarcic D, Fugosic V, et al. Dental trauma in children and young adults visiting a university dental clinic. *Dent Traumatol*. 2009; 25(1): 84-87. doi: [10.1111/j.1600-9657.2008.00711.x](https://doi.org/10.1111/j.1600-9657.2008.00711.x).
6. Bruns T, Perinpanayagam H. Dental trauma that require fixation in a children's hospital. *Dent Traumatol*. 2008; 24(1): 59-64. doi: [10.1111/j.1600-9657.2006.00508.x](https://doi.org/10.1111/j.1600-9657.2006.00508.x)
7. Petrovic B, Markovic D, Peric T, et al. Factors related to treatment and outcomes of avulsed teeth. *Dent Traumatol*. 2010; 26: 52-59. doi: [10.1111/j.1600-9657.2009.00836.x](https://doi.org/10.1111/j.1600-9657.2009.00836.x)
8. American Academy on Pediatric Dentistry Council on Clinical Affairs. A guideline on management of acute dental trauma. *Pediatr Dent*. 2008; 30(7): 175-183.
9. Fountain SB, Camp JH. Traumatic injuries. In: Cohen S, Burns

- AC, eds. *Pathways of the Pulp*. 6th ed. St Louis, Missouri, USA: Mosby; 1994.
10. Altun C, Ozen B, Esenlik E, et al. Traumatic injuries to permanent teeth in Turkish children, Ankara. *Dent Traumatol*. 2009; 25(3): 309-313. doi: [10.1111/j.1600-9657.2009.00778.x](https://doi.org/10.1111/j.1600-9657.2009.00778.x)
11. Cavalcanti AL, Bezerra PK, de Alencar CR, Moura C. Traumatic anterior dental injuries in 7-to 12-year-old Brazilian children. *Dent Traumatol*. 2009; 25(2): 198-202. doi: [10.1111/j.1600-9657.2008.00746.x](https://doi.org/10.1111/j.1600-9657.2008.00746.x)
12. Koroluk LD, Tulloch JF, Phillips C. Incisor trauma and early treatment for Class II division 1 malocclusion. *Am J Orthod Dentofacial Orthop*. 2003; 123(2): 117-125. doi: [10.1067/mod.2003.86](https://doi.org/10.1067/mod.2003.86)
13. Dearing SG. Overbite, overjet, lip-drape and incisor tooth fracture in children. *NZ Dent J*. 1984; 80(360): 50-52.
14. Ghose IJ, Baghdady VS, Enke H. Relation of traumatized permanent anterior teeth to occlusion and lip condition. *Community Dent Oral Epidemiol*. 1980; 8(7): 381-384. doi: <https://doi.org/10.1111/j.1600-0528.1980.tb01312.x>
15. O'Mullane DM. Some factors predisposing to injuries of permanent incisors in school children. *Br Dent J*. 1973; 134(8): 328-332. doi: <https://doi.org/10.1038/sj.bdj.4803000>
16. Ongkorahadjo A, Kusnoto B. The use of pre-implantation tooth lengths in the treatment of avulsed teeth. *J Clin Pediatr Dent*. 2000; 24(2): 91-95.
17. Kandemir S, Alpoz E, Caliskan M, Alpoz A. Complete replacement resorption after replantation of maxillary incisors: Report of a case. *J Clin Pediatr Dent*. 1999; 23(4): 343-346.
18. Andreasen JO, Malmgren B, Bakland LK. Tooth avulsion in children: To replant or not. *Endod Topics*. 2006; 14(1): 28-34. doi: [10.1111/j.1601-1546.2008.00224.x](https://doi.org/10.1111/j.1601-1546.2008.00224.x)
19. Petrovic B, Markovic D, Peric T, et al. Factors related to treatment and outcomes of avulsed teeth. *Dent Traumatol*. 2010; 26(1): 52-59. doi: [10.1111/j.1600-9657.2009.00836.x](https://doi.org/10.1111/j.1600-9657.2009.00836.x)
20. Bowden D, Patel H. Autotransplantation of premolar teeth to replace missing maxillary central incisors. *Br J Orthod*. 1990; 17(1): 21-28. doi: <https://doi.org/10.1179/bjo.17.1.21>
21. Czochrowska E, Stenvik A, Album B, Zachrisson B. Autotransplantation of premolars to replace maxillary incisors: A comparison with natural incisors. *Am J Orthod Dentofacial Orthop*. 2000; 118(6): 592-600. doi: [10.1067/mod.2000.110521](https://doi.org/10.1067/mod.2000.110521)
22. Paulsen H, Shi X, Welander U, Huggare J, Scheutz F. Eruption pattern of autotransplanted premolars visualized by radiographic color-coding. *Am J Orthod Dentofacial Orthop*. 2001; 119(4): 338-345. doi: [10.1067/mod.2001.114686](https://doi.org/10.1067/mod.2001.114686)
23. Czochrowska E, Stenvik A, Zachrisson B. The esthetic outcome of autotransplanted premolars replacing maxillary incisors. *Dent Traumatol*. 2002; 18(5): 237-245.
24. Czochrowska E, Stenvik A, Bjercke B, Zachrisson B. Outcome of tooth transplantation: survival and success rates 17-41 years posttreatment. *Am J Orthod Dentofacial Orthop*. 2002; 121(2): 110-119. doi: <https://doi.org/10.1067/mod.2002.119979>
25. Zachrisson B, Stenvik A, Haanaes H. Management of missing maxillary anterior teeth with emphasis on autotransplantation. *Am J Orthod Dentofacial Orthop*. 2004; 126(3): 284-298. doi: [10.1016/S0889540604005244](https://doi.org/10.1016/S0889540604005244)
26. Kokich V, Nappen D, Shapiro P. Gingival contour and clinical crown length: Their effects on the esthetic appearance of maxillary anterior teeth. *Am J Orthod*. 1984; 86(2): 89-94. doi: [10.1016/0002-9416\(84\)90300-2](https://doi.org/10.1016/0002-9416(84)90300-2)
27. Ostler MS, Kokich VG. Alveolar ridge changes in patients congenitally missing mandibular second premolars. *J Prosthet Dent* 1994; 71(2): 144-149. doi: [https://doi.org/10.1016/0022-3913\(94\)90022-1](https://doi.org/10.1016/0022-3913(94)90022-1)
28. Kramer P, Horst S, Konig J, Reston E, Ernani C. Rehabilitative treatment after unsuccessful teeth replantation: A case report. *J Clin Pediatr Dent*. 2002; 26(2): 119-124. doi: [10.17796/jcpd.26.2.h167116245217484](https://doi.org/10.17796/jcpd.26.2.h167116245217484)
29. Koford T, Wurtz V, Melsen B. Treatment of an ankylosed central incisor with single-tooth osteotomy and a simple distraction device. *Am J Orthod Dentofacial Orthop*. 2005; 127(1): 72-80. doi: [10.1016/j.ajodo.2003.12.020](https://doi.org/10.1016/j.ajodo.2003.12.020)
30. Spear F, Mathews D, Kokich VG. Interdisciplinary management of single-tooth implants. *Semin Orthod*. 1997; 3(1): 45-72. doi: [10.1016/S1073-8746\(97\)80039-4](https://doi.org/10.1016/S1073-8746(97)80039-4)