

## Review

### \*Corresponding author

James B. Martel, MD, MPH, FACS

California Northstate University  
College of Medicine

9700 West Taron Drive

Elk Grove, CA 95757, USA

Tel. (916) 686-7300

Fax: (916) 686-7310

E-mail: [james.martel@cnsu.edu](mailto:james.martel@cnsu.edu)

Volume 1 : Issue 2

Article Ref. #: 1000EMOJ1106

### Article History

Received: April 14<sup>th</sup>, 2015

Accepted: May 21<sup>st</sup>, 2015

Published: May 22<sup>nd</sup>, 2015

### Citation

Anders UM, Taylor EJ, Kravchuk V, Martel JR, Martel JB. Stevens-Johnson syndrome without skin lesions: a rare and clinically challenging disease in the urgent setting. *Emerg Med Open J.* 2015; 1(2): 22-30. doi: [10.17140/EMOJ-1-106](http://dx.doi.org/10.17140/EMOJ-1-106)

### Copyright

©2015 Martel JB. This is an open access article distributed under the Creative Commons Attribution 4.0 International License (CC BY 4.0), which permits unrestricted use, distribution, and reproduction in any medium, provided the original work is properly cited.

# Stevens-Johnson Syndrome without Skin Lesions: A Rare and Clinically Challenging Disease in the Urgent Setting

Ursula M. Anders<sup>1</sup>, Elise J. Taylor<sup>1</sup>, Victoria Kravchuk<sup>1</sup>, Joseph R. Martel<sup>1,2,3</sup> and James B. Martel<sup>1,2,3\*</sup>

<sup>1</sup>Research Department, Martel Eye Medical Group, 11216 Trinity River Drive, Rancho Cordova, 95670 CA, USA

<sup>2</sup>Graduate Medical Education, California Northstate University College of Medicine, 9700 West Taron Drive, Elk Grove, 95757 CA, USA

<sup>3</sup>Department of Ophthalmology, Dignity Health, 6501 Coyle Avenue, Carmichael, 95608 CA USA

## ABSTRACT

Stevens-Johnson syndrome, toxic epidermal necrolysis, and erythema multiforme are life threatening diseases causing mucocutaneous eruptions and can be difficult to manage medically. When oral tissues are involved, airway management can be of critical importance. Fluid and electrolyte imbalance are common and protocols to prevent secondary infection are initiated. All three conditions are rapidly evolving. Stevens-Johnson syndrome is more commonly associated with *Mycoplasma pneumoniae* in the pediatric population and drug hypersensitivity in adults, whereas erythema multiforme is mostly associated with herpes simplex virus in the adult population. These diseases are T-cell-mediated immune reactions, thought to represent a spectrum of the same disease. Clinical and immunohistochemical techniques are capable of differentiating Stevens-Johnson syndrome from erythema multiforme and provide insight into the possible underlying pathology creating the disease. Rare cases of Stevens-Johnson syndrome without skin manifestations have been associated with *Mycoplasma pneumoniae* and predominantly occur in males. In-hospital management is recommended to provide airway support, maintain fluid intake, electrolyte balance, obtain multi-specialty consultation, and to perform diagnostic testing. We describe a case of a 14 year old male with atypical Stevens-Johnson syndrome and a review of the literature.

**KEYWORDS:** Stevens-Johnson syndrome; Toxic epidermal necrolysis; Erythema multiforme; Immunohistochemical; Episcleritis; Ulcerative stomatitis; *Mycoplasma pneumoniae* associated mucositis (MPAM); Fuchs syndrome; Major histocompatibility class; Non-MPAM atypical Stevens-Johnson syndrome.

**ABBREVIATIONS:** MPAM: Mycoplasma pneumonia-associated mucositis; SJS: Stevens-Johnson syndrome; TEN: Toxic Epidermal Necrolysis; EM: Erythema Multiforme; HSV: Herpes Simplex Virus; MP: Mycoplasma Pneumonia; IVIg: Intravenous immunoglobulins; HLA: Human Leukocyte Antigen; TNF-alpha: Tumor Necrosis Factor-alpha.

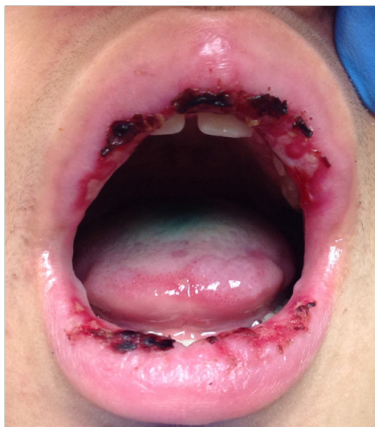## INTRODUCTION

Stevens-Johnson syndrome (SJS), Toxic Epidermal Necrolysis (TEN) and Erythema Multiforme (EM) are immune hypersensitivity disorders associated with drug or infectious exposure, which can be life threatening. SJS and TEN are believed to be the same disease, with TEN representing the more severe form of the disease spectrum. Historical information such as exposure to specific drugs or infections, and clinical information such as the characteristics of skin lesions and their distribution have been useful in differentiating between and SJS, TEN, or

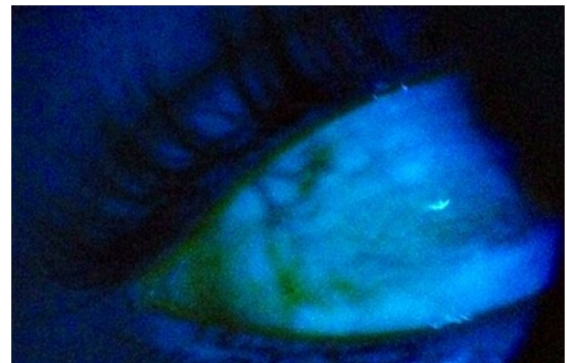
EM. Histologic and histochemical analyses remain the optimal methods of differentiating these diseases.<sup>1-4</sup> SJS, TEN, and EM are felt to be cytotoxic-mediated, and various strategies are used for management with newer treatment protocols being devised. Recent case reports describe rare variants of SJS without skin manifestations.

### CASE REPORT

A 14 year old previously healthy male with mild fever and malaise was seen by his primary care doctor for bilateral conjunctivitis and cough, for which he was prescribed azithromycin. After two doses he developed painful mouth swelling and the azithromycin was discontinued. This was similar to a previous reaction he had with penicillin three years earlier which resolved spontaneously after discontinuation. His symptoms worsened despite being off the azithromycin and he was prescribed oral prednisone, which was ineffective and discontinued after three days. He was referred to an ophthalmologist who felt his conjunctivitis represented a herpetic infection, and was started on ganciclovir ophthalmic gel and prednisolone acetate drops which he used for three days. He was subsequently seen by ENT who noted a new development of bleeding oral lesions and multiple blisters of the lips and oral mucosa (Figure 1). Magic mouthwash was prescribed. The patient experienced increasing difficulty with sustaining oral fluid intake and breathing due to his throat swelling, and was admitted to the hospital. On admission, the patient presented with dehydration, a non-productive cough, sensitivity to light, and blurred vision. A chest X-ray was performed and showed no abnormalities. On ophthalmologic examination, visual acuity was 20/20 in the right eye and 20/40 in the left eye. Pupils were equal, round and reactive to light. There was extensive ulceration of the conjunctiva of both eyes and diffuse fluorescein staining across the conjunctiva and cornea, with the left eye worse than the right. Focal episcleral injection in the right eye was noted (Figure 2). No adhesions or symblepharon were appreciated although inferior conjunctiva pseudomembrane formation was noted, right eye greater than the left. Funduscopic examination disclosed no abnormalities of the optic nerve, macula, or retinal vasculature.



**Figure 1:** Oral lesions seen in a 14 year old patient with Stevens-Johnson syndrome without skin lesions.



**Figure 2:** Episcleritis of the right eye show by fluorescein ophthalmic examination.

Blood serology disclosed a C-reactive protein of 1.61 mg/dL, white blood cell count of 8.6 K/UL, and was negative for mononucleosis, Herpes Simplex Virus (HSV) 1 and 2, human immunodeficiency virus, influenzae, and *Mycoplasma Pneumoniae* (MP) IgM antibody. MP IgG was mildly elevated at 0.65 U/L (0.09-0.33 U/L) and degressed to 0.35 U/L after one day. Mycoplasma PCR was negative in oral cavity lavage. Epstein Barr virus nuclear and capsid antigen IgG were positive with values of >8.0 (<0.91). Coxsackie B Virus Titers were negative with values <1:10 for Types 1,2,3,4, and 6. Coxsackie B Type 5 had a value of 1:20 (<1:10). Coxsackie A Type 9 titer was negative with a value of <1:8 (<1:8). The presumed diagnosis was SJS without skin lesions due to azithromycin hypersensitivity with concurrent Epstein-Barr infection.

The patient was discharged within four days of admission in stable condition. Ophthalmological follow-up disclosed healing of his episcleritis and conjunctival and corneal lesions after continued use of lubricant eye drops. Subsequent clinical follow ups showed complete resolution after one month.

### METHODS

We performed a systematic electronic literature search using the PubMed and Ovid MEDLINE databases. The last search was performed on April 7, 2015. The keywords used were: atypical Stevens Johnson syndrome, incomplete Stevens-Johnson syndrome, Stevens-Johnson syndrome without skin lesions, *Mycoplasma pneumoniae* associated mucositis, and Fuchs syndrome. All literature was limited to the English language.

Titles and abstracts were read to determine eligibility. Patients were included if they met the criteria for atypical SJS which included: lesions involving at least two mucous membranes (mouth, ocular, or genital), no skin involvement, and positive infection or suspected drug reaction.

### RESULTS

Our search yielded 1,192 publications that included the keywords listed in our methods section. 24 articles met the criteria for atypical SJS. In total, there were 32 patients described

including our reported patient. Patients were separated into two categories: children ages 3 to 16 years of age (17 patients, Table 1) and adults 18 to 44 years of age (15 patients, Table 2). Information for each case includes age, sex, chest involvement, genital involvement, etiology, diagnosis, diagnostic testing, and treatment. No patients under the age of 3 or over the age of 44 were reported in the literature.

Of the pediatric cases (Table 1), fifteen patients were male (88%), ten patients had chest involvement (59%), ten patients had genital involvement (59%), and fourteen patients had positive MP infection (82%). One was treated with immunosuppressants, all were treated with antibiotics (mainly macrolides), and one was treated with intravenous immunoglobulins (IVIg). All patients had a favorable outcome and all had complete resolution to their baseline health.

A prior review of atypical SJS by Vujic, et al. in 2014 yielded 818 search results, of which only 11 articles (13 patients) met their criteria.<sup>26</sup> The review was limited to adult patients between the ages of 18 to 38 years of age. Ten patients were male (77%), six patients had chest involvement (46%), nine patients had genital involvement (69%), and all patients had positive MP infection (100%). Nine were treated with immunosuppressants and ten were treated with antibiotics, which were mainly macrolides and fluoroquinolones.

For the adult cases, one case was excluded from Vujic, et al. for minimal skin involvement, and three more were included. Of those three additional cases, 2 were male, 2 had chest involvement, none had genital involvement, and two had positive MP infection. All were treated with immunosuppressants, two were treated with antibiotics, and one was treated with IVIg. All patients had a favorable outcome.

Four cases were not associated with MP (Table 1-2). Of the pediatric cases, one cause was unknown and two were from a suspected drug reaction. The presumed cause in the adult case was from MP despite having negative serological testing, although she did test positive for influenza type B.

## DISCUSSION

### Erythema Multiforme

EM, SJS, and TEN are acute, immune-mediated, hypersensitivity reactions to certain medications or infections, which are believed to trigger a cytotoxic response. EM was previously thought to be part of the spectrum of SJS and TEN, but today it is recognized as a distinct entity with different clinical and epidemiological characteristics.<sup>29,30</sup> EM is manifested by characteristically raised, bullous skin lesions that are palpable. Epidermal detachment occurs in less than 10% of the body surface area and there is minimal mucous membrane involvement. Oral lesions are described as polymorphic, erosive, ampullary, and erythema-

tosus.<sup>29</sup> EM occurs mostly in adults between 20 to 40 years old<sup>31</sup> and is most often caused by HSV.<sup>3,29,30</sup>

### Stevens-Johnson Syndrome

SJS was first described in 1922 by Albert Mason Stevens and Frank Chambliss Johnson.<sup>32</sup> It is considered to be a single disease entity with TEN, with less severity. The process begins with fever and flu-like symptoms, followed by a breakout of severe mucosal erosions and diffuse, flat atypical skin lesions that are non-palpable. SJS has a prevalence of 1.2-6 /million cases per year, with a mortality rate of 5-10%.<sup>4,33</sup> The most commonly identified cause of SJS in children is infection and drug sensitivity for adults.<sup>28,10,34,35</sup> Viral agents associated with SJS include coxsackie virus, HSV, AIDS, influenza, hepatitis, mumps, and Epstein-Barr. Associated bacterial agents include group A beta-hemolytic streptococci, diphtheria, brucellosis, lymphogranuloma venereum, mycobacteria, MP, rickettsia, tularemia, and typhoid.

### Atypical Stevens-Johnson Syndrome/*Mycoplasma Pneumoniae*-Associated Mucositis

The first case of atypical SJS was described by Maj Otto F. Sieber in 1967.<sup>11,19,23</sup> Most cases of this disorder have a better prognosis and recovery time than typical SJS, and to date there have been no mortalities from this condition. It is difficult to determine at the onset of this disorder if it will proceed to complete SJS or TEN. Ocular involvement occurs in every case and can include diffuse bullous conjunctival edema, pseudomembranes of the conjunctiva, corneal epithelial defects and episcleritis.<sup>14</sup> In 2005, Schallock and Dinulos proposed that the diagnosis of atypical SJS be classified as *Mycoplasma pneumoniae*-associated mucositis (MPAM) due to the striking feature that atypical cases of SJS are associated with MP.<sup>11</sup> MP is the most common cause of childhood pneumonia and is a self-limiting disease managed without antibiotics, which can explain why there is a better prognosis for MPAM.

In our review of the literature, four atypical cases were not associated with MP, therefore not fitting the criteria for MPAM (Tables 1 and 2). Of the pediatric cases, one cause was unknown and two were from a suspected drug reaction. The adult case was more complicated because the presumed cause was from MP despite having negative serological testing, only because the more likely cause of atypical SJS is from MP. The patient tested positive for influenza type B, which we suspect was the actual triggering factor. This suggests there may be other variant forms of atypical SJS, which we feel is the case for our patient. We suspect our patient developed a reaction to the azithromycin, which similarly occurred after a dose of penicillin three years prior with the exception of the mucosal necrosis. A similar case is described by Lamireau et al., of a 7-year-old boy that initially presented with non-MPAM atypical SJS, which recurred and resulted in a complete SJS.<sup>8</sup>

Author et al.	Age	Sex	Chest Involved	Genital Involved	Etiology	Diagnosis	Diagnostic Testing	Treatment*
Alter <sup>5</sup>	13	M	N	N	MP	MPAM	Complement fixation titer	Erythromycin
	10	M	Y	Y	MP	MPAM	Complement fixation titer	Erythromycin
	12	M	Y	Y	MP	MPAM	Complement fixation titer	Erythromycin
Bressan <sup>6</sup>	9	F	N/A	Y	MP	MPAM	IgM, agglutination assays	IVIg
Fearon <sup>7</sup>	8	M	Y	N	MP	MPAM w/ RSV	Agglutination assays	Roxithromycin
Lamireau <sup>8</sup>	6	M	Y	N	MP	SJS	Mouth culture, oral PCR, IgG, - cold agglutinin	Erythromycin, thalidomide
	7	M	N	N	Not Stated	SJS	Serology, - PCR	Rovamycin, prednisone
Latsch <sup>4</sup>	13	F	Y	Y	MP	SJS w/o skin lesions	Throat swab PCR, microparticle agglutination assay, IgM, -IgA, -IgG	Clarithromycin
	11	M	N	N	MP	SJS w/o skin lesions	Sputum specimen, microparticle agglutination assay, IgM, IgA, IgG	Clarithromycin
Meyer Sauteur <sup>9</sup>	7	M	Y	Y	MP	Fuchs	Throat swab PCR, complement fixation titer	Azithromycin
Ravin <sup>10</sup>	14	M	Y	Y	MP	Atypical SJS	Throat swab PCR	Cefuroxime, azithromycin
	16	M	Y	Y	MP	Atypical SJS	Throat swab PCR	Ceftriaxone, azithromycin
Schalock <sup>11</sup>	17	M	N/A	N	MP	MPAM	IgG	Azithromycin
Strawn <sup>12</sup>	15	M	Y	Y	Drug	Atypical SJS	N/A	Cefdinir, azithromycin
Trapp <sup>13</sup>	13	M	N/A	Y	MP	MPAM	IgM, - cold agglutinin	Azithromycin
Vanfleteren <sup>14</sup>	14	M	Y	Y	MP	SJS w/o skin lesions	IgG, IgM	Clarithromycin, amoxicillin-clavulanic acid, acyclovir
Ours	14	M	N	N	Drug	SJS w/o skin lesions w/ EBV	IgG, -IgM, - oral PCR, EBV NA IgG and CA IgG	Doxycycline

EBV: Epstein Barr Virus; RSV: Respiratory Syncytial Virus.

Age, sex, chest involvement, genital involvement, etiology, diagnosis, diagnostic methods, and treatment for 17 pediatric cases of atypical Stevens-Johnson syndrome. \*The literature shows a variability in initial treatment, with the ultimate treatment being focused on treating *Mycoplasma pneumoniae* or inflammation which is shown in this table.

**Table 1:** Pediatric cases of atypical Stevens-Johnson syndrome.

Author et al.	Age	Sex	Chest Involved	Genital Involved	Etiology	Diagnosis	Diagnostic Testing	Treatment*
Birch <sup>15</sup>	21	F	N/A	Y	MP	Atypical SJS	Esophageal biopsy, - PCR, IgM	IVIg, levofloxacin
Havliza <sup>16</sup>	32	F	N/A	N	MP	Fuchs	Antibody titers	Prenisolone, acyclovir, cefuroxime, levofloxacin
	38	F	N/A	N	MP	Fuchs	Antibody titers	Prenisolone, acyclovir, cefuroxime, levofloxacin
Hillebrand <sup>17</sup>	23	M	Y	Y	MP	Incomplete SJS	Throat swab PCR, agglutination IgM IgG titer	Amoxicillin-clavulanic acid, azithromycin
Kirke <sup>18</sup>	18	M	N	Y	MP	SJS	Oral biopsy, - immunofluorescence, IgM, complement fixation titer, cold agglutinin	Prednisolone
Li <sup>19</sup>	26	M	N	Y	MP	Fuchs	Oral biopsy, IgM, -cold agglutinin	Amoxicillin, oseltamivir, methylprednisolone, clarithromycin
Majima <sup>20</sup>	44	F	Y	N	Presumed MP	SJS-like mucositis w/o skin lesions	-IgM, + influenza B from nasal swab	Methylprednisolone, prednisolone, ampicillin, azithromycin
McGouran <sup>21</sup>	18	M	N	Y	MP	Atypical SJS	IgM	Methylprednisolone
Ramasamy <sup>22</sup>	19	M	Y	N	MP	Incomplete SJS	Complement fixation titer, agglutination assays, convalescent serum sample	Co-amoxiclav, erythromycin
Sieber <sup>23</sup>	22	M	Y	Y	MP	SJS	Throat swab, MP hemagglutination-inhibition, complement fixation titer	Prednisone, sodium cephalothin, tetracycline
Sternbersky <sup>24</sup>	22	M	N/A	Y	MP	Fuchs	IgG, IgM	Clarithromycin
Varghese <sup>25</sup>	20	M	Y	N	MP	MPAM	IgG, IgM, immunofluorescence	Levofloxacin, clindamycin, IVIg, methylprednisolone
Vujic <sup>26</sup>	23	M	Y	N	MP	MPAM	Oral mucosa biopsy, IgA, IgG, IgM, -immunofluorescence	Doxycycline, prednisolone
Walicka <sup>27</sup>	28	M	Y	Y	MP	SJS	Immunoenzymatic examination	Ceftriaxone, fluconazole, ciprofloxacin, cyclosporine A, fenoterol and ipratropium bromide (nebulizer), doxycycline, ambroxol, fenoterol
Yachoui <sup>28</sup>	29	M	N/A	Y	MP	Atypical SJS	IgM	Solumedrol

Age, sex, chest involvement, genital involvement, etiology, diagnosis, diagnostic methods, and treatment for 15 adult cases of atypical Stevens-Johnson syndrome. \*The literature shows a variability in initial treatment, with the ultimate treatment being focused on treating *Mycoplasma pneumoniae* or inflammation which is shown in this table.

**Table 2:** Adult cases of atypical Stevens-Johnson syndrome.



To our knowledge, there are only four reports of SJS associated with azithromycin,<sup>35-37</sup> with our case being the first described for atypical SJS. The first reported case describes a 5-year-old boy who developed oral pain and skin eruptions three days after taking azithromycin. Initial HSV testing was unremarkable, but showed an increase in IgM antibody after retesting. They suspected the HSV was reactivated after the use of steroids, which may explain the positivity for Epstein-Barr in our case.

### Genetic Predisposition

The underlying root for the spectrum of disease presentation and treatment responses between atypical SJS, MPAM, SJS, TEN and EM may have some underlying genetic influences. A strong genetic association can be formed by examining Human Leukocyte Antigen (HLA) typing, occurrences in family members, and recurrence. HLA-B\*5701, HLA-B\*5801, HLA-B\*1502, HLA-A\*3101, HLA-A\*0206, HLA-B\*4403, HLA-A29, HLA-B12, HLA-DR7, and HLA-A2 are linked to SJS drug hypersensitivity reactions.<sup>38-41</sup> HLA-DQB1\*0601, HLA-DQA1\*0103, DQB1\*0301, and HLA-A\*0206 are linked to ocular manifestations in SJS.<sup>42</sup> Genetic influences can explain why SJS occurs in multiple family members even though it is a rare condition<sup>43</sup> or why it recurs in certain individuals. Finkelstein, et al. reported 55 cases of SJS/TEN, of which 10 were reported to have a recurrence of SJS up to seven years after the initial episode.<sup>35</sup> The suspected initial triggers were from medication (5 cases), MP infections (3 cases), HSV infection (1 case), and influenza (1 case). Recurrences were from medication (2 cases), MP infection (4 cases), HSV infection (2 cases), and unknown (2 cases). Three patients had more than two recurrent episodes.

### Mechanism

SJS/TEN hypersensitivity reactions are mediated by cytotoxic T lymphocyte and natural killer cell responses resulting in keratinocyte death.<sup>44</sup> CD8+ T-cells recognize antigens bound to major histocompatibility complex I molecules, which activates two different types of cytotoxic signals. The first signal releases perforin, granzyme B, and granulysin which go into the cytosol of the target cell to eventually trigger apoptosis. The second signal includes the expression of FAS ligand which binds to FAS molecules on the surface of the target cell, leading to apoptosis. Keratinocyte death causes separation of the epidermis from the dermis, resulting in the blistering and classic skin lesions of typical SJS. This triggers cytokines (TNF-alpha), creating more inflammation and eventual necrosis.

### Diagnostic Methods

The diagnosis of MP is demonstrated by immunoglobulin diagnostic work up and PCR. The use of PCR is rapid and enables physicians to quickly diagnose and treat patients, although one case of positive MPAM by IgM and esophageal biopsy described a negative PCR report.<sup>15</sup> False negatives can occur as the

sensitivity of PCR ranges from 78-100%, while serology ranges from 50-66%.<sup>10</sup>

Skin biopsies are a definitive way to differentiate SJS/TEN from EM. Histopathological analyses typically show sub-epidermal blistering, widespread keratinocyte apoptosis, and full-thickness epidermal necrosis and detachment with a sparse dermal mononuclear infiltrate.<sup>44</sup> Differences can also be distinguished in their early stages. The number of granulysin- and perforin-expressing CD8+ cells are greater in SJS than EM, while the number of Foxp3 and CD4+ cells are lower.<sup>1</sup> However, this technique is unavailable in atypical cases where there are no skin lesions present. Oral biopsies have been performed for atypical SJS/MPAM, which show highly necrotic mucosa with extensive inflammatory infiltrate consistent with SJS.<sup>26</sup>

### Management and Treatment

There is a complexity of the treatment for a condition which may in the long run be self-limiting, however may evolve due to its complexity. Treatment with antibiotics and immunosuppressive agents remains the mainstay of management for patients with a suspected infectious cause. There are questions about efficacy and safety regarding the use of corticosteroids, however, an improvement in the disease indicates that there is an inflammatory component that needs to be treated. It is common for patients to be treated with an antiviral when there is a suspected viral infection or when being treated with corticosteroids. Patients with suspected adverse reactions to medication must be withdrawn from it. The use of plasmapheresis and hemodialysis to remove these agents is debated.<sup>44</sup> Macrolides are commonly used to treat MP infections, however there is an increase in resistance to this class of antibiotics. An estimated resistance rate of 27% was documented in the United States, and reaches up to 90% in China.<sup>45</sup> This is particularly challenging for children when there are not as many options for treatment because of potential toxicities.

Other treatments such as IVIg in patients with SJS, TEN, or EM are sometimes used to target Fas/FasL interactions, and are shown to have reduced mortality rates.<sup>44</sup> IVIg was used in only one case of atypical SJS which produced a good outcome (Table 2). Additional treatments include Tumor Necrosis Factor-alpha pathway antagonizers (TNF inhibitors, pentoxifylline, thalidomide, infliximab) and immunomodulators (cyclophosphamide, cyclosporine, N-acetylcysteine, and pentoxifylline) to reduce the amount of steroids.<sup>44</sup> Maintaining airway support and balancing nutritional and fluid intake is also crucial in improving the condition of these patients.

### CONCLUSION

EM, atypical SJS, MPAM, SJS, and TEN are all disorders which change rapidly and may pose life threatening consequences. Despite all therapeutic efforts, the mortality rate is increased with the severity of the disease, age of the patient, and

with any underlying medical condition. Chronic ocular complications and mucosal scarring may persist after treatment. We recommend that all patients with ocular, buccal and genital mucosa erosions have ophthalmologic, ENT and dermatologic consultation. Patients should be admitted in the acute setting, particularly when there are issues of airway integrity. This allows for greater patient stabilization, improved diagnosis, and better multi-specialty team approach to the complex and often unusual patient presentation.

#### ACKNOWLEDGEMENTS

The authors report no financial interests or conflicts of interest.

#### CONSENT STATEMENT

Consent was obtained by the patients father as patient was a minor.

#### REFERENCES

- Iwai S, Sueki H, Watanabe H, Sasaki Y, Suzuki T, Iijima M. Distinguishing Between erythema multiforme major and Stevens-Johnson syndrome/toxic epidermal necrolysis. *J Dermatol*. 2012; 39(9): 781-786. doi: [10.1111/j.1346-8138.2012.01532.x](https://doi.org/10.1111/j.1346-8138.2012.01532.x)
- Wetter DA, Davis MD. Recurrent erythema multiforme: clinical characteristics, etiologic associations, and treatment in a series of 48 patients at mayo clinic, 2000 to 2007. *J Am Acad Dermatol*. 2010; 62(1): 45-53. doi: [10.1016/j.jaad.2009.06.046](https://doi.org/10.1016/j.jaad.2009.06.046)
- Mockenhaupt M. The current understanding of Stevens-Johnson syndrome and toxic epidermal necrolysis. *Expert Rev Clin Immunol*. 2011; 7(6): 803-813. doi: [10.1586/eci.11.66](https://doi.org/10.1586/eci.11.66)
- Latsch K, Girschick HJ, Abele-Horn, M. Stevens-Johnson syndrome without skin lesions: case report. *J Med Microbiol*. 2007; 56(Pt 12): 1696-1699. doi: [10.1099/jmm.0.47318-0](https://doi.org/10.1099/jmm.0.47318-0)
- Alter SJ, Stringer B. *Mycoplasma pneumoniae* infections associated with severe mucositis. *Clin Pediatr*. 1990; 29(10): 602-604.
- Bressan S, Mion T, Andreola B, Bisogno G, Da Dalt L. Severe *mycoplasma pneumoniae*-associated mucositis treated with immunoglobulins. *Acta Paediatr*. 2011; 100(11): e238-e240. doi: [10.1111/j.1651-2227.2011.02342.x](https://doi.org/10.1111/j.1651-2227.2011.02342.x)
- Fearon D, Hesketh EL, Mitchell AE, Grimwood K. *Mycoplasma pneumoniae* infection complicated by pneumomediastinum and severe mucositis. *J Paediatr Child Health*. 2007; 43(5): 403-405. doi: [10.1111/j.1440-1754.2007.01088.x](https://doi.org/10.1111/j.1440-1754.2007.01088.x)
- Lamireau T, Leaute-Labreze C, Le Bail B, Taieb A. Esophageal involvement in Stevens-Johnson syndrome. *Endoscopy*. 2001; 33(6): 550-553. doi: [10.1046/j.1525-1470.2003.03012.x](https://doi.org/10.1046/j.1525-1470.2003.03012.x)
- Meyer Sauter PM, Goetschel P, Lautenschlager S. *Mycoplasma pneumoniae* and mucositis-part of the Stevens-Johnson syndrome spectrum. *J Dtsch Dermatol Ges*. 2012; 10(10): 740-746. doi: [10.1111/j.1610-0387.2012.07951.x](https://doi.org/10.1111/j.1610-0387.2012.07951.x)
- Ravin KA, Rappaport LD, Zuckerbraun NS, Wadowsky RM, Wald ER, Michaels MM. *Mycoplasma pneumoniae* and atypical Stevens-Johnson syndrome: a case series. *Pediatrics*. 2007; 119(4): e-1002-e1005. doi: [10.1542/peds.2006-2401](https://doi.org/10.1542/peds.2006-2401)
- Schalock PC, Dinulos JG. *Mycoplasma pneumoniae*-Induced Stevens-Johnson Syndrome without skin lesions: fact or fiction? *J Am Acad Dermatol*. 2005; 52(2): 312-315. doi: [10.1016/j.jaad.2004.07.044](https://doi.org/10.1016/j.jaad.2004.07.044)
- Strawn JR, Whitsel R, Nandagopal JJ, Delbello MP. Atypical Stevens-Johnson syndrome in an adolescent treated with duloxetine. *J Child Adolesc Psychopharmacol*. 2011; 21(1): 91-92. doi: [10.1089/cap.2010.0071](https://doi.org/10.1089/cap.2010.0071)
- Trapp LW, Schrantz SJ, Joseph-Griffin MA, Hageman JR, Waskow SE. A 13-year-old boy with pharyngitis, oral ulcers, and dehydration. *mycoplasma pneumoniae*-associated mucositis. *Pediatr Ann*. 2013; 42(4): 148-150. doi: [10.3928/00904481-20130326-06](https://doi.org/10.3928/00904481-20130326-06)
- Vanfleteren I, Gysel DV, De Brandt C. Stevens-Johnson syndrome: a diagnostic challenge in the absence of skin lesions. *Pediatr Dermatol*. 2003; 20(1): 52-56.
- Birch J, Chamlin S, Duerst R, Jacobsohn D. *Mycoplasma pneumoniae* and atypical Stevens-Johnson syndrome in a hematopoietic stem cell transplant recipient. *Pediatr Blood Cancer*. 2008; 50(6): 1278-1279. doi: [10.1002/pbc.21493](https://doi.org/10.1002/pbc.21493)
- Havliczka K, Jakob A, Rompel R. Erythema multiforme majus (fuchs syndrome) associated with *mycoplasma pneumoniae* infection in two patients. *J Dtsch Dermatol Ges*. 2009; 7(5): 445-448. doi: [10.1111/j.1610-0387.2008.06978.x](https://doi.org/10.1111/j.1610-0387.2008.06978.x)
- Hillebrand-Haverkort ME, Budding AE, bij de Vaate LA, van Agtmael MA. *Mycoplasma pneumoniae* infection with incomplete Stevens-Johnson syndrome. *Lancet Infect Dis*. 2008; 8(10): 586-587. doi: [10.1016/S1473-3099\(08\)70209-3](https://doi.org/10.1016/S1473-3099(08)70209-3)
- Kirke S, Powell FC. Mucosal erosions and a cough. *Ir Med J*. 2003; 96(8): 245.
- Li K, Haber RM. Stevens-Johnson syndrome without skin lesions (fuchs syndrome): a literature review of adult cases with mycoplasma cause. *Arch Dermatol*. 2012; 148(8): 963-964. doi: [10.1001/archdermatol.2012.681](https://doi.org/10.1001/archdermatol.2012.681)

20. Majima Y, Ikeda Y, Yagi H, Enokida K, Miura T, Tokura Y. Colonic involvement in Stevens-Johnson syndrome-like mucositis without skin lesions. *Allergol Int.* 2015; 64(1): 106-108. doi: [10.1016/j.alit.2014.08.010](https://doi.org/10.1016/j.alit.2014.08.010)
21. McGouran DC, Petterson T, McLaren JM, Wolbinski MP. Mucositis, conjunctivitis but no rash- the atypical Stevens-Johnson syndrome. *Acute Med.* 2011; 10(2): 81-82.
22. Ramasamy A, Patel C, Conlon C. Incomplete Stevens-Johnson syndrome secondary to atypical pneumonia. *BMJ Case Rep.* 2011; 2011. doi: [10.1136/bcr.08.2011.4568](https://doi.org/10.1136/bcr.08.2011.4568)
23. Sieber Of Jr, John TJ, Fulginiti VA, Overholt EC. Stevens-Johnson syndrome associated with *mycoplasma pneumoniae* infection. *JAMA.* 1967; 200(1): 79-81.
24. Sternbersky J, Tichy M. Fuchs' syndrome (Stevens-Johnson syndrome without skin involvement) in an adult male - a case report and general characteristics of the sporadically diagnosed disease. *Acta Dermatovenerol Croat.* 2014; 22(4): 284-287.
25. Varghese C, Sharain K, Skalski J, Ramar K. Mycoplasma pneumonia-associated mucositis. *BMJ Case Rep.* 2014; 2014.
26. Vujic I, Shroff A, Grzelka M, et al. *Mycoplasma pneumoniae*-associated mucositis - case report and systematic review of literature. *J Eur Acad Dermatol Venerol.* 2014; 1-4.
27. Walicka M, Majsterek M, Rakowska A, et al. *Mycoplasma pneumoniae*-induced pneumonia with Stevens-Johnson syndrome of acute atypical course. *Pol Arch Med Wewn.* 2008; 118(7-8): 449-453.
28. Yachoui R, Kolasinski S, Feinstein, D. *Mycoplasma pneumoniae* with atypical Stevens-Johnson syndrome: a diagnostic challenge. *Case Rep Infect Dis.* 2013; 2013: 457161. doi: [10.1155/2013/457161](https://doi.org/10.1155/2013/457161)
29. Bascones-Martínez A, García-García V, Meurman JH, Requena-Caballero L. Immune-mediated diseases: what can be found in the oral cavity? *Int J Dermatol.* 2014. doi: [10.1111/ijd.12681](https://doi.org/10.1111/ijd.12681)
30. Schneider G, Kachroo S, Jones N, et al. A systematic review of validated methods for identifying erythema multiforme major/minor/not otherwise specified, Stevens-Johnson syndrome, or toxic epidermal necrolysis using administrative and claims data. *Pharmacoepidemiol Drug Saf.* 2012; 21(Suppl 1): 236-239. doi: [10.1002/pds.2331](https://doi.org/10.1002/pds.2331)
31. Scully C, Bagan J. Oral mucosal diseases: erythema multiforme. *Br J Oral Maxillofac Surg.* 2008; 46(2): 90-95. doi: [10.1016/j.bjoms.2007.07.202](https://doi.org/10.1016/j.bjoms.2007.07.202)
32. Stevens AM, Johnson, FC. A new eruptive fever associated with stomatitis and ophthalmia report of two cases in children. *Am J Dis Child.* 1922; 24(6): 526-533. doi: [10.1001/archpedi.1922.04120120077005](https://doi.org/10.1001/archpedi.1922.04120120077005)
33. Hynes AY, Kafkala C, Daoud YJ, Foster CS. Controversy in the use of high-dose systemic steroids in the acute care of patients with Stevens-Johnson syndrome. *Int Ophthalmol Clin.* 2005; 45(4): 25-48.
34. Tay YK, Huff JC, Weston WL. *Mycoplasma pneumoniae* infection is associated with Stevens-Johnson syndrome, not erythema multiforme (von Hebra). *J Am Acad Dermatol.* 1996; 35(5 Pt 1): 757-760. doi: [10.1016/S0190-9622\(96\)90732-X](https://doi.org/10.1016/S0190-9622(96)90732-X)
35. Finkelstein Y, Soon GS, Acuna P, et al. Recurrence and outcomes of Stevens-Johnson syndrome and toxic epidermal necrolysis in children. *Pediatrics.* 2011; 128(4): 723-728. doi: [10.1542/peds.2010-3322](https://doi.org/10.1542/peds.2010-3322)
36. Aihara Y, Ito S, Kobayashi Y, Aihara M. Stevens-Johnson syndrome associated with azithromycin followed by transient reactivation of herpes simplex virus infection. *Allergy.* 2004; 59(1): 118. doi: [10.1046/j.1398-9995.2003.00336.x](https://doi.org/10.1046/j.1398-9995.2003.00336.x)
37. Brkljacic N, Gracin S, Prkacin I, et al. Stevens-Johnson syndrome as an unusual adverse effect of azithromycin. *Acta Dermatovenerol Croat.* 2006; 14(1): 40-45.
38. Pavlos R, Mallal S, Ostrov D, Pompeu Y, Phillips E. Fever, Rash and systemic symptoms: understanding the role of virus and hla in severe cutaneous drug allergy. *J Allergy Clin Immunol Pract.* 2014; 2(1): 21-33. doi: [10.1016/j.jaip.2013.11.005](https://doi.org/10.1016/j.jaip.2013.11.005)
39. Ueta M, Kaniwa N, Sotozona C, et al. Independent strong association of HLA-A\*02:06 and HLA-B 44:03 with cold medicine-related Stevens-Johnson syndrome with severe mucosal involvement. *Sci Rep.* 2014; 4: 4862. doi: [10.1038/srep04862](https://doi.org/10.1038/srep04862)
40. Shi YW, Min FL, Qin B, et al. Association between HLA and Stevens-Johnson syndrome induced by carbamazepine in southern han chinese: genetic markers besides B\*1502? *Basic Clin Pharmacol Toxicol.* 2012; 111(1): 58-64. doi: [10.1111/j.1742-7843.2012.00868.x](https://doi.org/10.1111/j.1742-7843.2012.00868.x)
41. Cheng CY, Su SC, Chen CH, Chen WL, Deng ST, Chung WH. HLA Associations and clinical implications in T-cell-mediated drug hypersensitivity reactions: an updated review. *J Immunol Res.* 2014; 2014: 565320. doi: [10.1155/2014/565320](https://doi.org/10.1155/2014/565320)
42. Power WJ, Saidman SL, Zhang DS, et al. HLA typing in patients with ocular manifestations of Stevens-Johnson syndrome. *Ophthalmology.* 1996; 103(9): 1406-1409.
43. Daubeney PE, Scopes JW. Recurrent Stevens-Johnson syn-



drome. *J R Soc Med*. 1991; 84(3): 168.

44. Su SC, Chung WH. Cytotoxic proteins and therapeutic targets in severe cutaneous adverse reactions. *Toxins*. 2014; 6(1): 194-210. doi: [10.3390/toxins6010194](https://doi.org/10.3390/toxins6010194)

45. Atkinson TP, Boppana S, Theos A, Clements LS, Xiao L, Waites K. Stevens-Johnson syndrome in a boy with macrolide-resistant *mycoplasma pneumoniae* pneumonia. *Pediatrics*. 2011; 127(6): e1605-e1609. doi: [10.1542/peds.2010-2624](https://doi.org/10.1542/peds.2010-2624)